



## Endoscopic Transesophageal Drainage of Mediastinal Abscess caused by Anastomotic Leakage after Esophagectomy

Fumihiko Kato, Kazuo Koyanagi, Jun Kanamori and Hiroyuki Daiko\*

Department of Esophageal Surgery, National Cancer Center Hospital, Tokyo, Japan

### Clinical Image

A 71-year-old male underwent salvage esophagectomy for residual cervical esophageal cancer after definitive chemo radiotherapy and reconstruction using gastric tube through the posterior mediastinal route. On Post Operative Day (POD) 8, Computed Tomography (CT) showed mediastinal abscess and swallowing contrast study demonstrated anastomotic leakage (Figure 1). Interventional CT-guided drainage was difficult because of the deep location of the abscess cavity; therefore, transesophageal drainage was tried. A guide wire was inserted into the abscess cavity through the leakage point assisted with transnasal endoscopy, and then, a 12-Fr drainage catheter was inserted over the guide wire (Figure 2). The catheter was gradually decannulated according to weekly radiological assessment. He started taking solid food on POD 110, and the catheter was finally removed on POD 148. Anastomotic leakage and subsequent mediastinal abscess after esophagectomy are serious complications associated with high morbidity and mortality [1]. This case indicates that transesophageal drainage of the mediastinal abscess assisted with endoscopy is a less-invasive, safe, and effective treatment that helps in avoiding surgical reintervention.

### OPEN ACCESS

#### \*Correspondence:

Kazuo Koyanagi, Department of Esophageal Surgery, National Cancer Center Hospital, Tsukiji 5-1-1, Chuo-ku, Tokyo, 104-0045, Japan, Tel: +81-3-3542-2511;

E-mail: [kkoyanag@ncc.go.jp](mailto:kkoyanag@ncc.go.jp)

Received Date: 22 Nov 2017

Accepted Date: 12 Dec 2017

Published Date: 20 Dec 2017

#### Citation:

Kato F, Koyanagi K, Kanamori J, Daiko H. Endoscopic Transesophageal Drainage of Mediastinal Abscess caused by Anastomotic Leakage after Esophagectomy. *Clin Surg*. 2017; 2: 1835.

Copyright © 2017 Kazuo Koyanagi.

This is an open access article distributed under the Creative Commons Attribution License, which permits unrestricted use, distribution, and reproduction in any medium, provided the original work is properly cited.

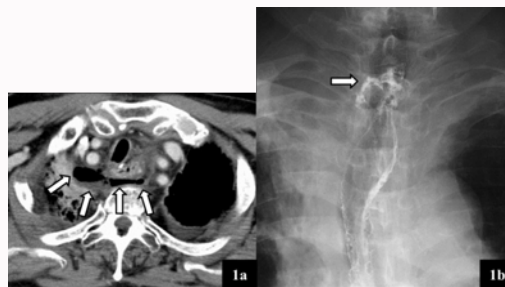


Figure 1: a: Computed tomography showed mediastinal abscess (arrow). b: Swallowing contrast study demonstrated anastomotic leakage (arrow).

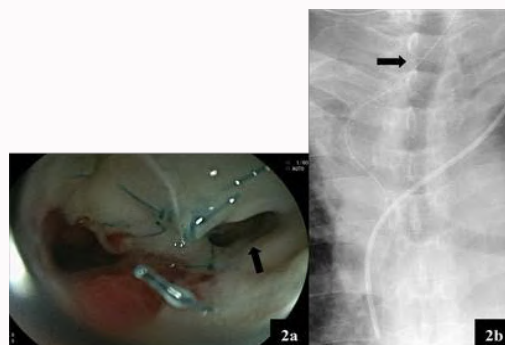


Figure 2: a: Upper endoscopy showed a fistula on the right wall of the suture line (arrow). b: The transesophageal drainage catheter was inserted into the mediastinal abscess through the fistula (arrow), assisted by endoscopy.

### References

1. Turrentine FE, Denlinger CE, Simpson VB, Garwood RA, Guerlain S, Aqurawal A, et al. Morbidity, mortality, cost, and survival estimates of gastrointestinal anastomotic leaks. *J Am Coll Surg*. 2015;220(2):195-206.