



## Angiomyxoid Bladder Tumour in Young Women

*Obi-Njoku Obinna\* and Hitendra Rpatel*

*Department of Surgery, Princess Alexandra Hospital, Hamstel Road Harlow, Essex, UK*

### Clinical Image

The bladder is an uncommon site for an aggressive Angiomyxoid tumour. We have recently managed 2 females in their 20's. Both had lower urinary tract symptoms and microscopic haematuria. After they underwent standard diagnostic work up (ultrasound, cystoscopy and biopsy) a diagnosis of angiomyxoid tumour was made (Figure 1A and 1B). This rare tumour is considered as an aggressive, benign lesion, and initial management is localized excision, followed by imaging to quantify if there is any recurrence. So far, both our patients had aggressive endoscopic resection without recurrence at 1 year.

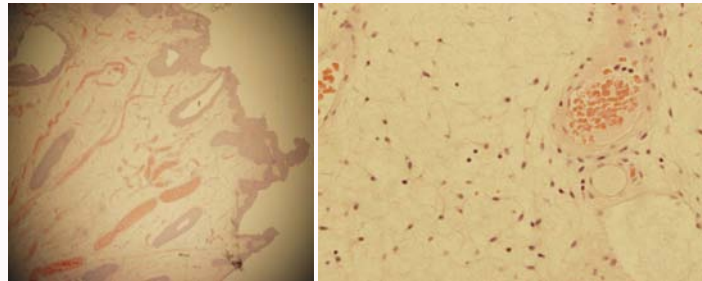


Figure 1A and 1B: Angiomyxoid tumour.

### OPEN ACCESS

#### \*Correspondence:

Obi-Njoku Obinna, Department of Surgery, Princess Alexandra Hospital, Hamstel Road Harlow, Essex, UK, Tel: +447947192090;

E-mail: [obinna.obi-njoku@pah.nhs.uk](mailto:obinna.obi-njoku@pah.nhs.uk)

Received Date: 02 Oct 2017

Accepted Date: 22 Nov 2017

Published Date: 01 Dec 2017

#### Citation:

Obinna O-N, Rpatel H. Angiomyxoid Bladder Tumour in Young Women. *Clin Surg.* 2017; 2: 1798.

**Copyright** © 2017 Obi-Njoku Obinna. This is an open access article distributed under the Creative Commons Attribution License, which permits unrestricted use, distribution, and reproduction in any medium, provided the original work is properly cited.