



Trans-Scrotal Complex Fistula-in-Ano: Tricks for Safe Single Stage Surgery

Rajvilas Anil Narkhede, Gunjan S Desai* and Hitesh Mehta

Department of Gastrointestinal Surgery, Lilavati Hospital and Research Centre, India

Keywords

Complex fistula; Trans-scrotal fistula; Trans-sphincteric fistula

Clinical Image

Complex fistula-in-ano with tract extending trans-scrotally to the root of penis and secondary opening at base of scrotum is very rare. Fistula-in-ano with scrotal extension is known to present as inter-sphincteric or low trans-sphincteric fistula running through the Colles' fascia, which is the path of least resistance over a tough deep perineal Gallaudet's fascia and often stands out as exception to Goodsall's rule [1,2]. Present images show surgical technique for managing one such case. Digital examination under anesthesia revealed a palpable thickening at 12 O'clock; 2 cm proximal to anal verge which on probing identified a long fistulous tract with trans-scrotal extension to root of penis and a secondary opening at the base of scrotum (Figure 1-3). A careful sharp fistulectomy was performed, starting from root of penis, dissecting tract in the scrotal septum without violating the testes with its tunica and was brought out infra-scrotally. The secondary tract opening at base of scrotum was watchfully dissected, palpating the 'cord like feel' of foley's catheter, thus preventing any iatrogenic injury to urethra. After complete fistulectomy, internal opening was closed with absorbable sutures and partial primary wound closure was performed. Recovery was uneventful (Figure 4-6). In conclusion, single stage surgery is feasible option and safe dissection in correct tissue planes holds the key to successful outcome for complex trans-scrotal fistula-in-ano.

OPEN ACCESS

*Correspondence:

Gunjan S Desai, Department of Gastrointestinal Surgery, Lilavati Hospital and Research Centre, Mumbai, Maharashtra, 400050, India;

E-mail: dsshsh@yahoo.com

Received Date: 21 Sep 2017

Accepted Date: 17 Nov 2017

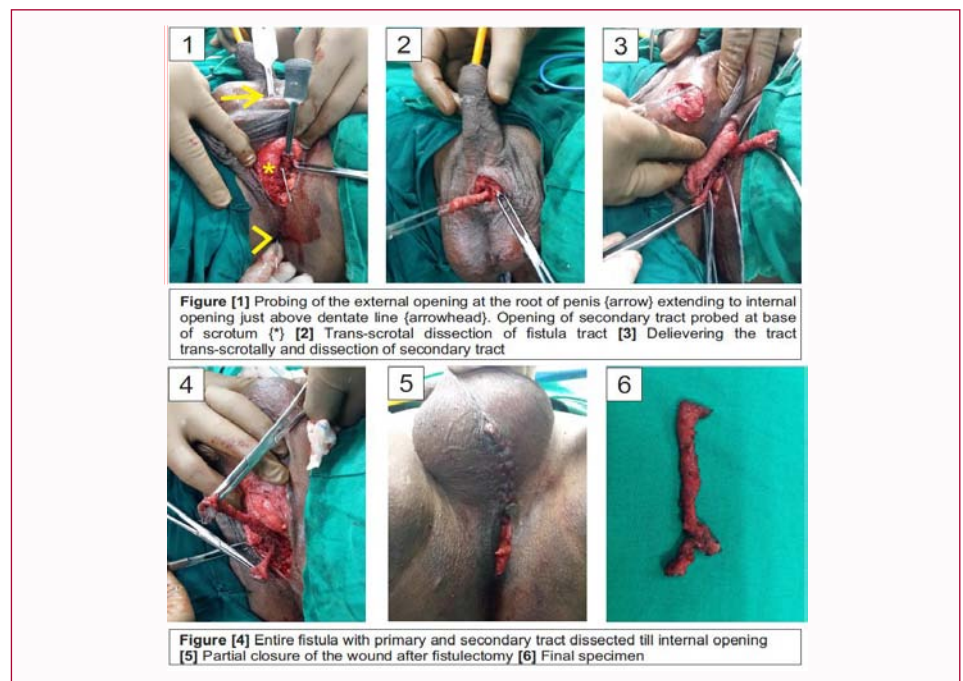
Published Date: 29 Nov 2017

Citation:

Narkhede RA, Desai GS, Mehta H. Trans-Scrotal Complex Fistula-in-Ano: Tricks for Safe Single Stage Surgery. Clin Surg. 2017; 2: 1774.

Copyright © 2017 Gunjan S Desai.

This is an open access article distributed under the Creative Commons Attribution License, which permits unrestricted use, distribution, and reproduction in any medium, provided the original work is properly cited.



References

1. Araki Y, Kagawa R, Yasui H, Tomoi M. Rules for anal fistulas with scrotal extension. J Anus Rectum Colon. 2017;1(1):22-8.
2. Shinde PS. Management of rare, low anal anterior fistula exception to Goodsall's rule with Kārasūtra. Anc Sci Life. 2014;33(3):182-5.