



Secretory Carcinoma of the Parotid Gland: First Case Reported in Brazil

Jônatas C de Freitas¹, Rodrigo S Honório², Liandra R de S Barbosa^{3*}, Francieudo J Rolim¹ and Luís AA Ferreira¹

¹Department of Surgery, Federal University of Ceará-UFC, Brazil

²Department of Pathology, Albert Sabin Children's Hospital, Brazil

³Department of Medicine, Federal University of Ceará, Brazil

Abstract

The Mammary Analogue Secretory Carcinoma or MASC was first described by Skálová et al. [2]. In most cases, it presents as a low-grade histological tumor, with a low degree of aggressiveness and a relatively benign course; however, it has the potential to undergo a high-grade malignant transformation. The MASC usually presents as a nodule or small mass in the region of the parotid gland, which is not associated with any other symptoms. Here we report the case of patient treated in of Head and Neck Surgery Service of the Medical School of Federal University of Ceará with a nodule in the parotid region for whom a parotidectomy was indicated. The histopathological examination showed the presence of a mammary analogue secretory carcinoma, the first case reported in Brazil, to the best of our knowledge. Due to the compromised margins and extensive perineural invasion, adjuvant radio therapy was indicated. The patient is in good overall condition, with no evidence of disease after one year of treatment.

Introduction

The salivary gland secretory carcinoma was recently added to the WHO classification of neck and head tumors in its 4th edition in 2017 [1], a term covering the neoplasia first described by Skálová et al. [2] as the mammary analogue secretory carcinoma or MASC. It is a very rare tumor that mainly affects the parotid gland [3].

To date, more than 100 cases of MASC [4] have been described. It seems to have a higher incidence in men than in women and it usually has as low course; however, sometimes there may be locally advanced disease, with lymph node involvement [5]. This type of tumor is characterized by the great similarity in the presentation of its morphological and immunohistochemical characteristics with the also rare secretory carcinoma of the breast.

The aim of the present study is to report the case of a patient with a mammary analogue secretory carcinoma treated at the Head and Neck Surgery Service of the Walter Cantídio University Hospital, which, to the best of our knowledge is the first case reported in Brazil.

Case Presentation

A 44-year-old female patient, with no prior comorbidities, sought medical attention after observing a nodule growth in the left parotid region, measuring approximately 3 cm, without facial paralysis or other clinical manifestations. Ultrasonography revealed a solid intra-glandular superficial nodular lesion, and partial left parotidectomy was indicated. Fine-needle aspiration biopsy was not diagnostic.

The histopathological analysis result of the anatomical specimen was not conclusive, also showing extensive perineural invasion and surgical margin compromised by the neoplasia (Figures 1-3), suggesting a malignant neoplasia, raising the initial hypotheses of mucoepidermoid carcinoma, mammary analogue carcinoma, acinar cell carcinoma or adenocarcinomas with No Other Specification (NOS).

The immunohistochemical analysis was strongly reactive for S100 and mammaglobin (Figure 4), and the combination of morphological and an immunohistochemical finding was compatible with the diagnosis of mammary analogue secretory carcinoma in the parotid gland. Due to the presence of extensive perineural invasion and compromised surgical margins, the patient was

OPEN ACCESS

*Correspondence:

Liandra R de S Barbosa, Department of Medicine, Federal University of Ceará, Brazil, Tel: 55 (85) 3366.8063; Fax: 55

(85) 3366.8064;

E-mail: liandrarsbarbosa@gmail.com

Received Date: 12 Dec 2018

Accepted Date: 04 Jan 2019

Published Date: 07 Jan 2019

Citation:

de Freitas JC, Honório RS, de S Barbosa LR, Rolim FJ, Ferreira LAA. Secretory Carcinoma of the Parotid Gland: First Case Reported in Brazil. Clin Surg. 2019; 4: 2286.

Copyright © 2019 Liandra R de S Barbosa. This is an open access article distributed under the Creative Commons Attribution License, which permits unrestricted use, distribution, and reproduction in any medium, provided the original work is properly cited.

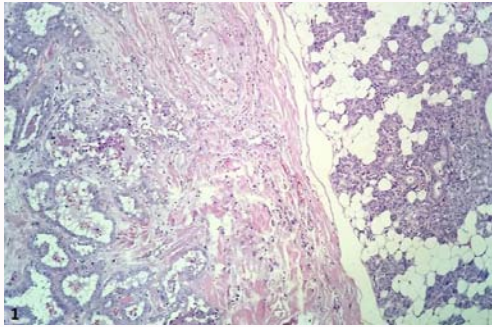


Figure 1: Parotid secretory carcinoma (left) and normal salivary glandular tissue (right) HE.

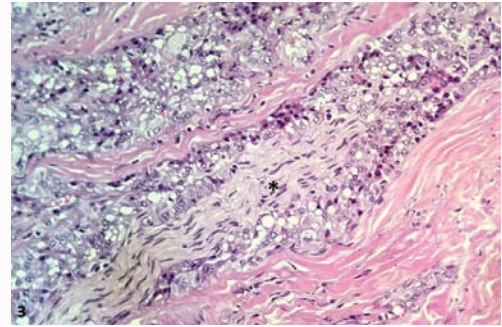


Figure 3: Parotid secretory carcinoma with perineural infiltration. Neural fillet (*) surrounded by vacuolated neoplastic cells HE.

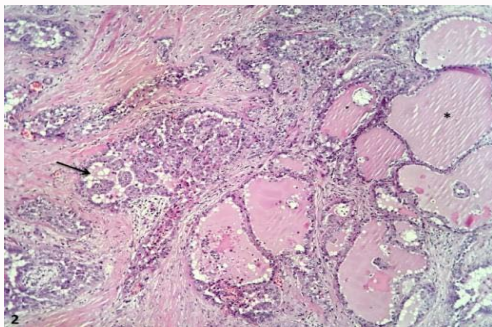


Figure 2: Parotid secreting carcinoma with follicular (right, *) and papillary (arrow) arrangements HE.

referred for adjuvant radiotherapy and is in good overall condition with no evidence of disease after one year of treatment.

Discussion

The MASC was first described by Skálóva in 2010 in a clinical-pathological study of 16 salivary gland tumors 2 that had characteristics that resembled the histomorphology found in secretory carcinomas of the breast. Since then, in recent years, more than 90 cases of MASC have been described [4,6], based mainly on retrospective studies, which may indicate that the tumor is not as rare as previously thought, but rather a tumor that has been scarcely

studied (Table 1). Most published studies have a description of the immunohistochemical and genetic characteristics as their main focus, and the knowledge about clinical presentation and tumor progression is still limited. In most of the reports used in this research, as in the case presented by our patient, clinical presentation at the time of diagnosis is summarized as the appearance of a nodule or swelling in the region of the affected salivary gland, usually the parotid, from a few months to little more than one year of evolution and no association with other symptoms [3,5-7,10,11]. However, other symptoms were also observed, such as weight loss [11], pain [8], skin infiltration [8], cervical lymphadenopathy [7,8] and ulceration of the affected region [4,8]. The MASC is considered a low-grade carcinoma with as low course and favorable prognosis [4,9] however, both local involvement and lymph node metastasis may occur [5,7].

Histologically, its resemblance to the secretory carcinoma of the breast is striking. In most cases, MASC has microcystic or solid tubular structures, cells with vacuolated cytoplasm, with abundant eosinophilic secretory material and oval to round vesicular nuclei [3,7,12] however, it is possible to observe a less common presentation, with the tumor dominated by large cysts with multilayer coating, exhibiting tubular, follicular or papillary architecture, with occasional occurrence of solid areas. The neoplastic gland secretions are strongly positive for Periodic Acid-Schiff (PAS) staining [12]. Our patient had, at the histopathological analysis of the surgical specimen obtained at the partial parotidectomy, neoplasia of atypical epithelial cells, with

Table 1: Characteristics of patients with MASC diagnostic in nine case series.

Author	Year	Number of cases	Male/Female	Age	Site	Lymph node involvement
[2]	2010	16	9/7	21-75	Parotid (n=13) Minor salivary gland (n=1) Palate (n=1) Lips(n=1)	There was no lymph node involvement in any of the cases
[5]	2012	1	0/1	34	Parotid (n=1)	No
[3]	2014	1	0/1	58	Parotid (n=1)	No
[7]	2014	4	1/3	28-83	Parotid (n=1) Minor salivary gland (n=2) Submandibular gland (n=1)	Yes (n=1)
[4]	2014	1	0/1	41	Palate (n=1)	Sim
[8]	2014	7	5/2	17-73	Parotid (n=6) Palate (n=1)	Sim (n=3)
[11]	2015	2	2/0	42,60	Parotid (n=2)	N/I
[9]	2015	1	1/0	66	Parotid (n=1)	No
[6]	2016	3	1/2	09-45	Parotid (n=3)	No

N/I: No Information

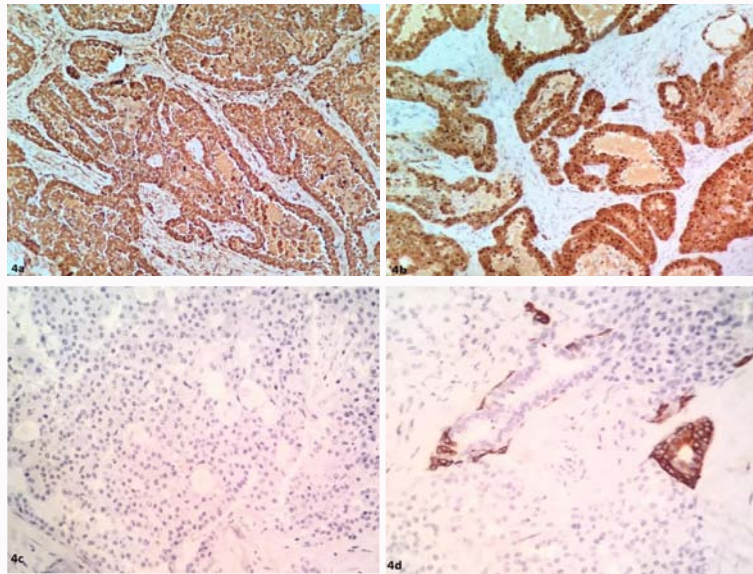


Figure 4: A positively marked parotid secretory carcinoma for mammaglobin (A), S100 (B) and negativity for DOG-1 (C) CK14 (D), in the latter with residual salivary gland labeling t.

large, vesicular nuclei, generally with evident nucleoli, in addition to cells with acinar arrangement, focally of microcystic, ductal and occasionally follicular aspect, having also a solid arrangement and papillary outlines. There was also the presence of extensive perineural invasion and compromised surgical margin. As with the secretory carcinoma of the breast, MASC is positive for proteins such as mammaglobin, vimentin and S-100, and is non-immunoreactive to estrogen receptor, progesterone receptor and negative for Her2 (triple negative); furthermore, it shares a specific gene mutation, the translocation $t(12;15)(p13;q25)$ that leads to the formation of the ETV6-NTRK3 oncogene [4,9,12] identical to that found in the secretory carcinoma of the breast. The gene resulting from the ETV6-NTRK3 fusion encodes a chimeric tyrosine kinase that has the potential to undergo a malignant transformation and plays a major role in oncogenesis [8,14]. This genetic characteristic has also been found in congenital fibrosarcoma, mesoblastic nephroma, and acute myeloid leukemia [7]. Our patient showed strongly reactive immunohistochemistry for S100, AE1/AE3 and mammaglobin and was negative for calponin, GCDPF-15, CK14 and DOG1.

Therefore, we realized that the MASC has specific histological and immunohistochemical characteristics, which together would be sufficient to attain its diagnosis. However, it also has characteristics that overlap with those of other types of salivary gland cancers [2,12], which may hinder the diagnosis. Mucoepidermoid carcinoma, acinar cell carcinoma and adenocarcinoma with NOS are the major tumors that can be mistakenly diagnosed as MASC [6].

Conclusion

Although considered to be a rare condition, studies related to mammary analogue secretory carcinoma in salivary glands show that an under diagnosis of this entity has been occurring, due to its similarities to other types of cancer considered to be more common, and that it is always important to consider it in the differential diagnosis of mucoepidermoid carcinomas, adenocarcinomas with NOS and acinar cell carcinomas. Moreover, studies concerning the treatment and follow-up of this recent pathology are required.

References

1. El-Naggar AK, Chang JKC, Grandis JR, Takata T, Slootweg PJ. WHO classification of Head and Neck Tumors. 4th edn, IARC. 2017.
2. Skalova A, Vanecek T, Sima R, Laco J, Weinreb I, Perez-Ordoñez B, et al. Mammary analogue secretory carcinoma of salivary glands, containing the ETV6-NTRK3 fusion gene: a hitherto undescribed salivary gland tumor entity. *Am J Surg Pathol.* 2010;34(5):599-608.
3. Sethi R, Kozin E, Remenschneider A, Meier J, VanderLaan P, Faquin W, et al. Mammary analogue secretory carcinoma: Update on a New Diagnosis of Salivary Gland Malignancy. *The Laryngoscope.* 2014;124(1):188-95.
4. Luo W, Lindley SW, Lindley PH, Krempel GA, Seethala RR, Fung K-M. Mammary analog secretory carcinoma of salivary gland with high-grade histology arising in hard palate, report of a case and review of literature. *Int J Clin Exp Pathol.* 2014;7(12):9008-22.
5. Levine P, Fried K, Krevitt LD, Wang B, Wenig BM. Aspiration biopsy of mammary analogue secretory carcinoma of accessory parotid gland: another diagnostic dilemma in matrix-containing tumors of the salivary glands. *Diagn Cytopathol.* 2014;42(1):49-53.
6. Oza N, Sanghvi K, Shet T, Patil A, Menon S, Ramadwar M, et al. Mammary analogue secretory carcinoma of parotid: Is preoperative cytological diagnosis possible? *Diagn Cytopathol.* 2016;44:519-25.
7. Serrano-Arévalo ML, Mosqueda-Taylor A, Domínguez-Malagón H, Michal M. Mammary Analogue Secretory Carcinoma (MASC) of salivary gland in four Mexican patients. *Medicina Oral, Patología Oral y Cirugía Bucal.* 2015;20(1):e23-9.
8. Majewska H, Skálová A, Stodulski D. *Virchows Arch.* 2015;466(3):245.
9. Balanzá R, Arrangoiz R, Cordera F, Muñoz M, Luque-de-León E, Moreno E, et al. Mammary analog secretory carcinoma of the parotid gland: A case report and literature review. *Int J Surg Case Rep.* 2015;16:187-91.
10. Inaba T, Fukumura Y, Saito T, Yokoyama J, Ohba S, Arakawa A, et al. Cytological Features of Mammary Analogue Secretory Carcinoma of the Parotid Gland in a 15-Year-Old Girl: A Case Report with Review of the Literature. *Case Rep Pathol.* 2015;2015:656107.
11. Salat H, Mumtaz R, Ikram M, Din NU. Mammary Analogue Secretory Carcinoma of the Parotid Gland: A Third World Country Perspective-A Case Series. *Case Rep Otolaryngol.* 2015;2015:697254.

12. Skalova A. Mammary Analogue Secretory Carcinoma of Salivary Gland Origin: An Update and Expanded Morphologic and Immuno histochemical Spectrum of Recently Described Entity. *Head and Neck Pathol.* 2013;7(Suppl 1):30-6.
13. Jung MJ, Song JS, Kim SY, Nam SY, Roh JL, Choi SH, et al. Finding and Characterizing Mammary Analogue Secretory Carcinoma of the Salivary Gland. *Korean J Pathol.* 2013;47(1):36-43.
14. Chiosea SI, Griffith C, Assaad A, Seethala RR. Clinico pathological characterization of mammary analogue secretory carcinoma of salivary glands. *Histopathology* 2012;61(3):387-94.