



Peri-Articular Reconstruction for Intra-Articular Calcaneal Fractures Utilizing the Ilizarov Method with Orthofix Truelok Circular External Fixator: A Technique Guide and Orthoplastic Considerations

Edgardo Rodriguez-Collazo^{1*} and Joseph Agyen²

¹Department of Surgery, Presence Saint Joseph Hospital, USA

²Department of Podiatric Surgery Resident, Presence Saint Joseph Hospital, USA

Abstract

Calcaneal fractures have been a challenging injury for the surgeon to treat for some time. Poor soft tissue envelope, vascular compromise and poor overall health are some of the obstacles surgeons face before entering the operating room. Several techniques exist including Open Reduction and Internal Fixation (ORIF) with lateral plate and screws, percutaneous techniques of reduction with k-wires and reduction by external fixation. The purpose of this technique guide is to provide a comprehensive approach to the treatment of calcaneal fractures when ORIF is not indicated. One long-term study showed that the functional outcomes of ORIF were statistically the same as non-operative treatment in displaced intra-articular fractures. Forty-seven patients with 47 calcaneal fractures were treated with the reduction traction and Ilizarov method of circular external fixation. All fractures were classified using the Sanders CT classification system with 27 patients Sanders III or IV fractures (20 patients). The average age was 37 with a range of 28 to 55. The mean follow-up time was 32 months with a minimum of 28 months. The average post-op AOFAS hindfoot score was 81.25. All patients were allowed to bear 20% of weight starting at post-operative day #0. We present a technique for reduction of Sanders stage III and IV calcaneal fractures by means of external fixation. The senior author presents a long-term retrospective analysis using this particular technique with favorable outcomes. Using indirect reduction and external fixation with the Ilizarov method we can limit complications and improve functional outcomes of intra-articular calcaneal fractures.

Keywords: Calcaneal fracture; Ilizarov; Trauma; External fixator; Orthoplastic approach; Orthofix truelok; Reduction traction

Introduction

Historical perspective

Calcaneal fractures are relatively common injuries to the foot amounting to approximately 60% of foot fractures. The large majority is extra-articular and can be treated non-operatively. The small portions of fractures that involve the articular surface are the injuries that become difficult to treat and fuel the debate on appropriate technique for reduction. Cotton and Wilson were some of the first to recognize difficulty in open reduction internal fixation and became advocates of closed reduction. Their method included reducing the lateral blow out fragment by impacting the fracture fragments [1].

Bohler was originally involved in describing mechanics of the fracture back in the 1930's. He pushed for anatomic reduction by hanging the foot in plantar flexion and using traction to reduce the fracture. By plantar flexion of the foot, the space between talus and calcaneus was increased to restore height and joint space. He measured success by the tuber-joint angle, now known as Bohler's angle, in his post-reduction radiographs [2]. Later in the 1930's techniques for percutaneous pin placement were described with plaster cast immobilization to maintain reduction.

In 1935, dissatisfied with long term outcomes, Conn became a proponent of the triple arthrodesis for improperly aligned fractures that went on to heal. He discussed loss of arch height and increase pronation that provided disabling pain to the patient [3]. Gallie, approximately 10 years later,

OPEN ACCESS

*Correspondence:

Edgardo Rodriguez-Collazo,
Department of Surgery, Director
Chicago Foot & Ankle Deformity
Correction Center, Ilizarov Correction
& Microsurgical Limb Reconstruction
Presence Saint Joseph Hospital,
Chicago, USA,
E-mail: egodpm@gmail.com

Received Date: 01 Jun 2018

Accepted Date: 21 Jun 2018

Published Date: 28 Jun 2018

Citation:

Rodriguez-Collazo E, Agyen J. Peri-Articular Reconstruction for Intra-Articular Calcaneal Fractures Utilizing the Ilizarov Method with Orthofix Truelok Circular External Fixator: A Technique Guide and Orthoplastic Considerations. *Clin Surg*. 2018; 3: 1998.

Copyright © 2018 Edgardo Rodriguez-Collazo. This is an open access article distributed under the Creative Commons Attribution License, which permits unrestricted use, distribution, and reproduction in any medium, provided the original work is properly cited.

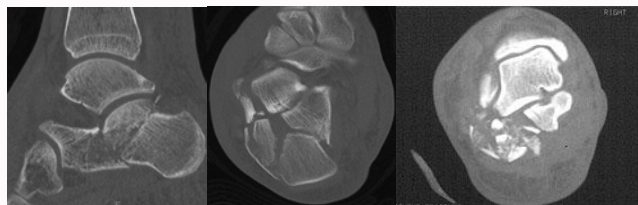


Figure 1: Pre-op CT imaging of calcaneal fractures showing comminution and joint involvement.

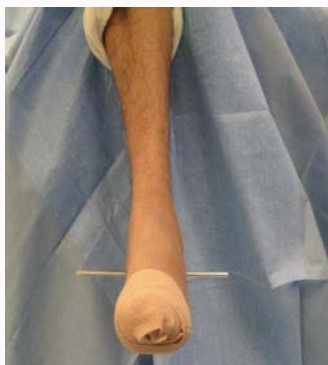

Figure 2: After the foot is placed at 90 degrees to the leg, a 3/16-inch Steinman pin is driven just inferior to the peroneal tendons from lateral to medial through the tuber of the calcaneus.

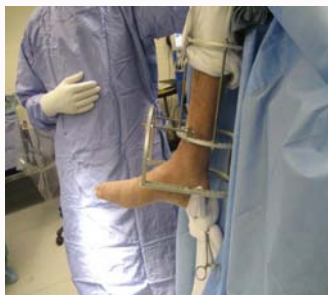

Figure 3: 20 to 25 lbs of weights are attached to the Steinman pin for distraction and reduction.

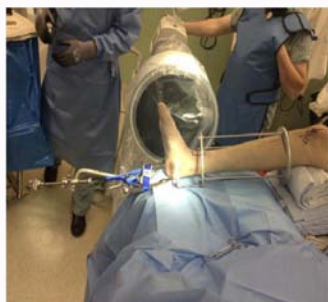

Figure 4: Traction external device that can be used for traction and reduction.

recommended isolated subtalar joint arthrodesis for fractures that had healed with persistent joint pain [4]. In the late 1940's to early 1950's, Essex-Lopresti and Palmer published results of 90% excellent patient satisfaction and return to work 4 to 8 months later with open reduction and restoration of the joint surface augmented with bone graft [5,6].

Ali in 2009 reduced intra-articular fractures of the calcaneus with

the Ilizarov technique and found it as a good alternative to traditional methods with fewer secondary problems [7]. Throughout the years to follow mixed opinions of open reduction and closed reduction ensued. Large complication rates pushed some to pursue non-operative therapy. Despite several advances in technique and fixation, there is still a debate on this topic.

Indications and contraindications

Poor soft tissue envelope indicated clinically by significant edema, fracture blisters and lack of signal on Doppler analysis of the descending peroneal artery are several indications for choosing external fixation. Others include severe comminuted and displaced fractures, consistent with Sanders III and IV classifications. Patients with co-morbidities that may delay healing including diabetes, history of alcohol or tobacco use, vitamin and protein deficiencies also favor reduction by external fixation in severe fractures. It is the author's opinion that the only contraindication to using this method is the patient's ability to tolerate the visual concept of wearing an external fixation device for several months.

Surgical technique

Patient preparation: Three radiographic views of the tibia-fibula including the foot are obtained as well as a CT scan prior to surgery for perioperative planning (Figure 1). Routine pre-op labs in addition to vitamin D and calcium levels are obtained. A nutritional assessment is obtained on a per patient basis that may include protein, albumin, pre-albumin, vitamin D and total lymphocyte counts. Furthermore, measurement of patient's leg diameter for proper fixator rings size and length of tibial block. The need for suspensory wire and proper pin placement can also be determined with use of pre-operative imaging.

Pre-op adjunct procedure: A pre-operative popliteal block is recommended to aid in post-op analgesia.

Patient positioning: The first step in the application is proper positioning of the patient. Anatomic landmarks should be evaluated to ensure appropriate positioning. The anterior crest of the tibia should align with the second metatarsal and second toe to ensure the foot is neither internally nor externally rotated. A leg holder positioned at knee joint allowing the leg to hang approximately at a 60-degree angle to allow traction of the posterior tuber improving the calcaneus inclination and height of the calcaneus.

Axial traction: With the foot placed at 90 degrees to the leg, a 3/16-inch Steinman pin is driven just inferior to the peroneal tendons from lateral to medial through tuber of the calcaneus (Figure 2). The Steinman pin should exit inferior to the tarsal tunnel following the varus or valgus hindfoot malalignment allowing the surgeon to derotate the heel with weights (Figure 3) or traction external device (Figure 4). We suggest using 20 to 25 lbs of weight hung from the Steinman pin while manually manipulating the calcaneus to restore length and width. One can also use a traction table to assist in distal and plantar distraction.

Frame construct

A static external fixator (Orthofix Truelok external fixator) is used for treatment of calcaneal fractures while being distracted. It should be assembled intra-op without wire placement so that it can be applied around the calcaneal pin used for skeletal traction. It consists of a long tibial block with 2 full rings connected by threaded rods, a foot plate, and half ring. The tibial rings should be sized based on the patient's

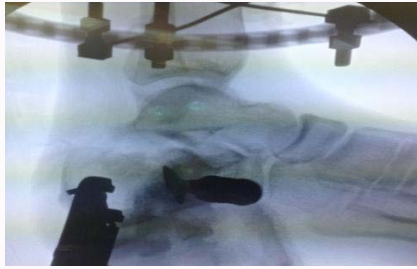


Figure 5: The use of a straight osteotome to maneuver and realign the joint.

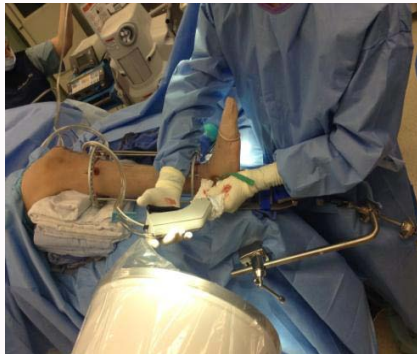

Figure 6: Lavage of the joint to help combat arthrosis.

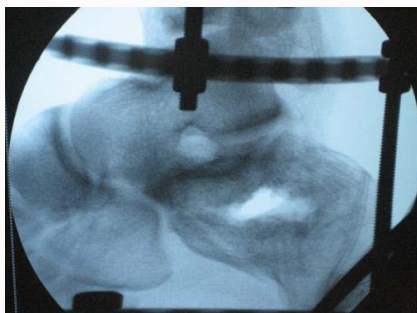


Figure 7: A large void may occur and can be backfilled with allograft.

leg girth so that 2 fingers breadths are able to fit between ring and leg. Four threaded rods are equally spaced and used for the connection and the frame is then checked in the frontal and sagittal planes.

Fracture Reduction: Under fluoroscopic guidance, triangulate the posterior facet and insert a 3/16-inch Steinman pin from inferior to superior to elevate posterior facet. This pin is used in conjunction with skeletal traction to joystick and manipulates the posterior fragment. A small incision is made to the lateral aspect of the calcaneal tuber just inferior to the posterior facet. Under fluoroscopy, a small to medium straight osteotome is placed just inferior to the posterior facet and maneuvered (Figure 5).

This allows the surgeon to elevate the facet until joint realignment is achieved under fluoroscopy. If in your pre-operative imaging studies the fragment is found to be severely depressed, a pair of pliers can be used for extra leverage in conjunction to the osteotome. Lavage of the joint after realignment can be preformed to help prevent arthrosis (Figure 6). Often times a large bone void will be created and can be backfilled with allograft (Figure 7).

When proper realignment is established, the lateral radiograph

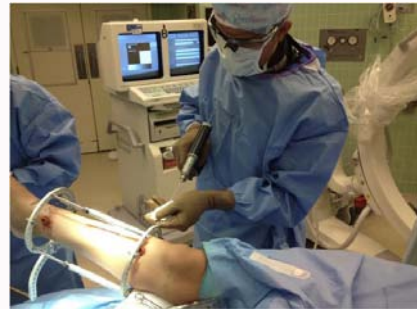

Figure 8: A minimum of two wires per ring is essential for stability with wire angles at 60 degrees and one placed above and below the ring.

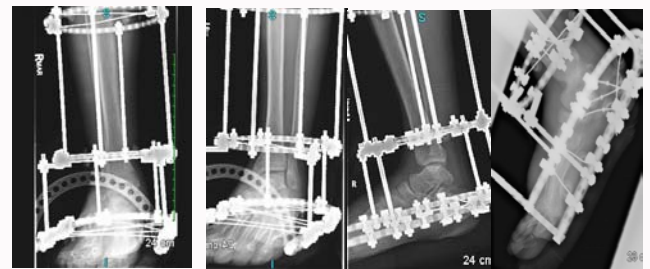


Figure 9: Final external fixator construct.

will show an overlap of the lateral process of the talus with the posterior facet, thus giving the appearance that the joint is not congruent; however, in reality realignment is established.

Application of the external fixator

Wire placement technique: Minimum of two wires per ring is essential for stability with wire angles at 60 degrees. One wire is placed above the ring and one wire below (Figure 8). Simultaneous tensioning at 130 kg is performed to ensure adequate wire tension when fixed to frame. The tibial block wires are secured prior to fracture reduction.

The external fixation frame is provisionally stabilized with one transverse transosseous wire for each ring and bone segment. The author prefers to hold the transosseous wire with an alcohol or cold saline soaked gauze during the insertion process to minimize cross-contamination and to decrease the temperature across the wire during insertion. We have found by placing all transosseous wires (smooth transosseous wires, olive wires) and half pins in a sterile ice bath in turn decreasing thermal necrosis during application. After placement of the transverse transosseous wires, positioning is performed clinically.

The second step is to further stabilize each bone segment and level of the external fixator with an additional tensioned transosseous wire. The oblique transosseous wires are placed on the opposite side of the ring, superior or inferior, to which the transverse transosseous wire were placed to increase stability. These wires should be inserted at approximately 60-degree angle from the transverse transosseous wire. After appropriate positioning of the wires and external fixator, the transosseous wires are tensioned with a dynamometric tensioner. The transosseous wires exiting posteriorly should be tightened with a wrench and the anterior wires should be finger tightened and dual tension to 130 kg of force. Next a transosseous wires should be placed through the forefoot taking care to plantar flex the 1st ray during insertion. The forefoot wire will be tensioned at the end to 90 kg.

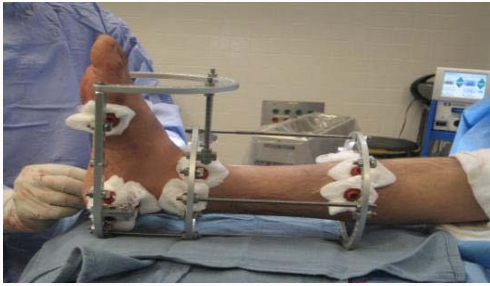

Figure 10: Final fixator position on foot and leg and pin site dressings immediately post-op.

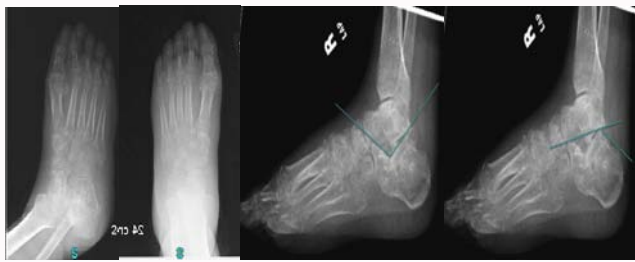

Figure 11: Post-operative films of a stage IV sanders calcaneal fracture reduction utilizing ilizarov method with orthofix truelok circular external fixator. A) Oblique view. B) AP view. C) Lateral view showing angle of Gisseane's after reduction approximately 105 degrees. (Normal~120-140) D) Lateral view showing Bohler's angle after approximately 36 degrees (Normal~25-40).

Once the wires are secured and proper tensioning is achieved, the calcaneal olive wire is inserted. This wire is directed from medial to lateral and inferior to the tarsal tunnel. This wire is tightened with a wrench medially and tensioned with a dynamometric tensioner laterally. Fracture reduction is held in place via ligamentotaxis. To maintain distraction, the nuts are tightened to secure the tibial block to the foot plate. The traction is disengaged and removed at this time.

A posterior facet suspensory wire is inserted from lateral to medial with fluoroscopic guidance so that the wire sits just inferior the facet to prevent any future joint depression. The wire often will not sit flush with fixator and may need to be posted to allow for attachment of the wire to the ring. This wire should then be tensioned to approximately 90 kg of force. The forefoot wire can now be tensioned to approximately 90 kg of force (Figure 9). Only applied if after reduction and bone grafting there is radiographic evidence of declination of the posterior facet (not needed if reduction is seen).

Any incisions are now sutured together with suture of the surgeon's choice including the larger opening from the Steinman pins using peroxide, the skin and fixator are cleaned thoroughly (Figure 10). A bulky sterile dressing consisting of abdominal padding and kerlix is placed and left intact for 12-14 days.

Post-op protocol

Weight-bearing status

- Patients are allowed to start weight bearing at 20% with a 4-point pick-up rolling walker immediately post operatively. Explain to the patient that weight bearing is strongly encouraged as it promotes callus formation and bone healing. Furthermore, ambulatory activity decreases the formation of post-operative deep vein thrombosis.
- Patients are discharged with a rolling walker or crutches. Rolling walkers are preferred due to increased stability and better

control of a 20% weight bearing status. A consult to physical therapy is needed prior to patient discharge to ensure adequate ambulation capabilities using the rolling walker.

Dressing

- The original post-op dressing is to remain intact for 12-14 days.
- After the initial dressing change within the office setting, the ex-fix can be sprayed with Isopropyl alcohol around each pin. Sterile 4 × 4's are placed around each wire to protect the skin/pin interface from the environment.
- After the initial dressing change, the patient is education on cleaning the frame themselves. Instruct the patient to no touch the wire or remove any eschar. Patient's with poor soft tissue envelop are advised not to clean wires on their own and should be done only by the surgeon. The patient can clean the frame approximately every 3 days. Furthermore, once all wires are dry/stable and there is no evidence of drainage/irritation, the patient is allowed to shower and swim with application of alcohol immediately after (not earlier than 2 weeks). Patients with poor soft tissue envelop, long-standing diabetes and poor compliance rate may never submerge the external fixator in water and pin site care must be performed by surgeon or professional care provider.
- A footpad can be made with foam heel protector and incorporated into the dressing for assistance in weight bearing activity. A rigid sole surgical shoe can also be modified and applied.

- The entire frame is to be covered with either elastic bandage to protect the frame from the environment.

Warning signs

- During the post-operative course, the patient is educated on the signs and presentation of a pin site infection (Redness, swelling, pain and discharge). A prescription for antibiotics is dispensed to the patient. The patient is also instructed to return to the office within 24 hours. Infections that appear deep or non-resolving require admission for IV antibiotics to prevent osteomyelitis.
- Erythema and mild drainage is normally due to a loose, unstable wires (not due to infection), which can be resolved by tightening using the "Russian Technique." Another cause may be due to increased skin tension around the wire that can be relieved by performing a stab incision. Granulomas are common around pin sites and can be resolved with silver nitrate.
- Deep vein thrombosis is minimized by the patient's early weight bearing status.
- Wire breakage is occasionally seen but by proper tensioning of the wires intra-operatively decreases this complication. The suspensory wire aids in prevention of joint collapse, which is left in place until complete consolidation is noted.

Antibiotics

- Oral antibiotics are a surgeon's preference, but Augmentin 875 mg 1 tab PO BID × 14 day is commonly used for superficial pin infection.
- Ciprofloxacin and Clindamycin combination for Penicillin allergic patients.
- Zyvox 600 mg for infection that do not respond to

Augmentin.

Post-op pain

- Patients are generally admitted 23 hours for pain control immediately post-operatively, but upon discharge should be placed on Tylenol #3 or any oral analgesic regimen the surgeon prefers. We prefer using a triad of pain relievers including; Tramadol 100 mg, Lyrica 50 mg and Tylenol #3 for post-operative outpatient pain management.
- While in the hospital a PCA pump is ordered per anesthesia. Titration of the PCA is recommended by day 2 and transitioned to Tylenol #3 upon discharge. Tramadol can also be used in conjunction with the Tylenol #3.
- Recommend a popliteal block pre-operatively by anesthesia to greatly minimize post-operative pain or possibly eliminate the need for admission.
- Never use Toradol or NSAIDs due to decrease of bone healing. Communication with anesthesia is important as Toradol is frequently administered at the end of cases.

Removal of Ex-Fix

- A CT scan is ordered to confirm bone regeneration and consolidation of fracture fragments. Once this is verified the patient can be scheduled for fixator removal (Figure 11).

Results

Data collected from 2000 to 2013, 47 calcaneal fractures were treated with the above method. All were classified to be Sanders III (27 patients) or IV fractures (20 patient). Of the 47-calcaneal fractures, 12 were female and 35 were male. The average age was 37 with a range of 28-55. The mean follow-up time was 32 months with a minimum of 28 months. Co-morbidities included 33 patients with osteoporosis, 16 patients with DM type 2, 7 patients with renal disease and 8 patients (males) with severely poor soft tissue envelope. Furthermore, 11 patients had a current history of smoking (8 males) and 21 patients were considered to have obesity due to abnormal BMI (18 Male; 3 Female). There were no open fractures and 1 case was a bilateral injury. All cases were done under fluoroscopy using demineralized bone matrix (Integra-Evo3c). The average time in the fixator was 13 weeks, which corresponds to radiographic healing time.

Once the external fixator was removed and patient returned to pre-injury activities, the patients were evaluated with the AOFAS hindfoot and ankle score for pain and functionality. The average post-op score was 81.25. All patients were allowed to bear 20% of weight starting at post-operative day #0. In this series of 47 calcaneal fractures, no cases of wound dehiscence from the lateral incision were reported. In 3 cases, superficial pin tract infections were reported, all of which whom were DM type II and resolved with oral antibiotics. In 3 cases transient sural neuritis was reported. Residual varus deformity was reported in 5 subjects that further required subsequent calcaneal slide procedures to correct. Subtalar joint collapse was reported in 7 patients. Finally, additional corrective procedures involving subtalar joint fusion was performed in 7 patients with symptomatic Subtalar joint arthrosis.

Discussion

We present a series of comminuted calcaneal fractures reduced with Ilizarov method utilizing the TruLock orthofix external fixation. Talarico et al. [8] reviewed 25 fractures over 7 years and noted 92% good and excellent results with the Maryland Foot Score (MFS). They also noted ROM >50% of the uninjured side in 21 of 25 fractures.

It is our opinion that skeletal traction and reduction of calcaneal fracture with the Ilizarov method is a viable technique for the treatment of comminuted Sanders III and IV injuries. It can also be used in open fractures as well as those associated with soft tissue compromise, whether that is from the injury itself or patient's comorbidities. It allows immediate reduction of the fracture, while open methods often mandate a delay in repair due to the poor soft tissue envelope. This technique also allows for immediate weight bearing after surgery.

Conclusion

The application of the external fixator can be technically challenging and requires a basic knowledge of frame biomechanics and cross-sectional anatomy; however, the reduction of the fracture follows the basic principles of skeletal traction. Joint distraction can also be incorporated and maintained with the repair. The complications are limited and with proper technique and attention to detail, these complications are further minimized. The outcomes of the reduction with Ilizarov stabilization then become predictable and favorable compared to the open technique.

References

1. Cotton FJ, Wilson LT. Fractures of the os calcis. *Boston Med Surg J.* 1908;159(18):559-65.
2. Böhler L. Diagnosis, pathology and treatment of fractures of the os calcis. *J Bone Joint Surg.* 1931;13(1):75-89.
3. Conn HR. The treatment of fractures of the os calcis. *J Bone Joint Surg.* 1935;17:392.
4. Gallie WE. Subastragalar arthrodesis in fractures of the os calcis. *J Bone Joint Surg.* 1943;25(4):731-6.
5. Essex-Lopresti P. The mechanism, reduction technique and results in fractures of the os calcis. *Br J Surg.* 1952;39(157):395-419.
6. Palmer I. Mechanisms and treatment of fractures of the os calcis. *J Bone Surg.* 30-SA, 2-8.
7. Ali AM, Elsaied MA, Elmoghazy N. Management of calcaneal fractures using the Ilizarov external fixator. *Acta Ortho Belg.* 2009;75(1);51-6.
8. Talarico L, Vito GR, Zyryanov SY. Management of displaced intra-articular calcaneal fractures by using external ring fixation, minimally invasive open reduction and early weight bearing. *J Foot Ankle Surg.* 2004;43(1);43-50.