



## Limb Salvage in Extremity Soft Tissue Sarcoma

Munir Alam\*

Department of Plastic Surgery, Faisal Hospital, Pakistan

### Abstract

**Objective:** To evaluate the role of plastic surgical techniques in limb salvage of extremity Soft Tissue Sarcoma (STS). Historically, the surgical treatment of soft tissue sarcoma does not routinely discuss reconstruction option because amputation was the mainstay of the treatment. The acceptable treatment protocol for extremity sarcoma has evolved to include limb-sparing resection of the tumor in combination with radiation and/or chemotherapy.

**Study Design:** Retrospective case series analytic study.

**Setting:** Department of Plastic Surgery, HMG Olaya Medical Centre, Riyadh, KSA and Department of Plastic Surgery, Independent Medical College, Faisalabad, Pakistan.

**Period:** From July 2011 to June 2016.

**Material and Methods:** A total of six patients with the extremity STS were included in this study.

Three male and 3 female patients were included in this study that underwent for surgical resection and reconstruction. Patients who were unresectable tumors or not fit for surgery were excluded from the study.

**Results:** We have achieved the better results with plastic surgical techniques after limb-sparing resections in selected group of patients and improvement in the survival rate. One patient out six had recurrence six months after the excision and reconstruction of extremity STS and did not survive and got rest in peace after eight months due to local and regional recurrence.

**Conclusion:** We recommend reconstructive plastic surgical procedures for the management of extremity STS to avoid limb amputation and less loss of function. The patients have a better quality of life, superior function, improved self-esteem, and an intact body image.

**Keywords:** Sarcoma; Extremity; Limb salvage; Plastic surgery

### OPEN ACCESS

#### \*Correspondence:

Munir Alam, Department of Plastic Surgery, Faisal Hospital, Independent Medical College, 46 University Town, Millat Road, Faisalabad, Pakistan, Tel:

+92-3217711360;

E-mail: mrmuniralam@gmail.com

**Received Date:** 06 Sep 2019

**Accepted Date:** 07 Oct 2019

**Published Date:** 21 Oct 2019

#### Citation:

Alam M. Limb Salvage in Extremity Soft Tissue Sarcoma. *Clin Surg*. 2019; 4: 2620.

**Copyright** © 2019 Munir Alam. This is an open access article distributed under the Creative Commons Attribution License, which permits unrestricted use, distribution, and reproduction in any medium, provided the original work is properly cited.

### Introduction

Extremity STS are rare mesenchymal malignancies [1] that account for approximately 1% of all cancers in adults and about 10% to 15% in children. Extremity soft tissue sarcomas are heterogenous tumors that vary in biological aggressiveness, treatment option and response, manifestation site, and cytogenetic background as compared to other malignancies.

Historically, the surgical treatment of soft tissue sarcoma does not routinely discuss reconstruction option because amputation was the mainstay of the treatment. The acceptable treatment protocol for extremity sarcoma has evolved to include limb-sparing resection of the tumor in combination with radiation and/or chemotherapy. We have achieved the better results after limb-sparing resections in selected group of patients and improvement in the survival rate. The patients have a better quality of life, superior function, improved self-esteem, and an intact body image (Figure 1).

When the STS have been treated definitely, then the regular follow up of the patient is required for any potential development of local, regional or distant metastasis [1,2].

### Material and Methods

This study is retrospective cross sectional analytic study. All of these six patients presented electively to the Plastic Surgical outpatient services in the tertiary care hospital. There were three male and three female patients. Most of the patients were above the age of 50 years. Overall number of patients with extremity STS were higher in number seen in the outpatient department. Only those patients who underwent surgical resection and reconstruction were included in this study. All other patients who were not fit for surgery and unresectable extremity STS were excluded from the study.

In our plastic and reconstructive practice, we see patients who had inadequate tumor resection resulting in local/regional recurrence, extensive ulceration, irradiation damage, wound healing disturbances, and functional deficiencies after muscle group resection. In this study, inclusion criteria for only those patient who underwent complex flap reconstruction after excision of extremity STS.

All the patients were followed up at initially 3 months and then every 6 months.

## Results

Total numbers of patients in this study were six. There were equal gender distribution including three males and three females' patients and most of the patients above the age of 50 years (Table 1).

Most common tumors in this group of six patients were high grade pleomorphic sarcoma (50% of the patients). Out of total three, one patient each had high grade synovial sarcoma (17%); intermediate malignant schewanoma (17%) and one patient had low grade leiomyosarcoma (17%) (Table 2).

In our group of patients though small in number, careful preplanned surgical excision and reconstruction of the limb with either regional or free flap and adjuvant therapy of extremity STS confers long term survival.

Only one patient, who was treated for high grade recurrent lower limb pleomorphic sarcoma developed local and regional recurrence six months after the wide local excision and reconstruction with medial gastrocnemius muscle flap and covered with split thickness skin graft. Probably may be due to the fact the recurrent tumors involved cortex of the middle third of the tibia. Although careful wide resection of the soft tissue and bony cortex performed and offered the post op chemotherapy, patient did not survive and rest in peace eight months after the excision of extremity STS and reconstruction (Figure 2).

The chances of local recurrence rate after the resection of extremity STS and postoperative radiotherapy have been reported in the literature as high as 20% [3,4], however, the recent reports narrate the local recurrence rate is almost less than 10% [5-8].

## Discussion

In our plastic and reconstructive practice, we see patients who had inadequate tumor resection resulting in local/regional recurrence, extensive ulceration, irradiation damage, impaired wound healing, and functional deficiencies after muscle group resection. Surgical resection with preservation of the limb has become the standard of care in treatment of extremity STS of the extremities.

There are various classification system used in the clinical practice for the extremity STS. The two commonly used staging system for extremity benign and malignant tumors including STS of the musculoskeletal system are Enneking staging system and TNMG. Enneking have also classified benign tumors which is not the scope of this article [9-11].

In my clinical practice, I have found Enneking staging system of extremity STS is the most useful as compared to other classification system [10,12]. Furtherance, Enneking describe the surgical grade (G, G1, G2), the extent of the tumor (T, T1, T2) and hematogenous spread (Mo, M1). The patient with extremity STS is assigned a stage after compilation of all the clinical, radiological and histological data

**Table 1:** Clinical Staging-Enneking's Classification.

Sr. Number	Gender (Male/Female)	Age	Staging
1	F	50 Yrs	3
2	M	63 Yrs	2b
3	M	45 Yrs	2a
4	F	57 Yrs	2a
5	M	64 Yrs	1a
6	F	68 Yrs	2b

**Table 2:** Histological Types of Soft Tissue Sarcoma.

Sr. Number	Grade	Tissue of Origin
1	High	Pleomorphic sarcoma
2	High	Pleomorphic sarcoma
3	High	Synovial Sarcoma
4	Low	Leiomyosarcoma
5	Intermediate	Malignant Schewanoma
6	High	Pleomorphic sarcoma

of the patient [1,2,13].

Enneking's classification

1A: Low grade intracompartmental sarcoma

1B: Low grade extracompartmental sarcoma

2A: High grade intracompartmental sarcoma

2B: High grade extracompartmental sarcoma

3: Regional or distant metastasis

The Musculoskeletal Tumour Society (MSTS) have also adopted the Enneking staging system [14]. Most of the patients in our experience were stage IIa & IIb, where tumor resection and reconstruction was performed, represent the similarity described by Enneking et al. [9,10,15]. This shows reliability, reproducibility and provide prognostic information about extremity STS. There are various factors which are involved in choosing the proper therapy for the patients, the most commonly used factors are stage of the disease, age of the patient, functional outcome after the surgery, the type of adjuvant therapy, whether or not therapy preoperative and postoperative [10,16].

The MSTS guidelines for the treatment of extremity STS described as

### Stage IA

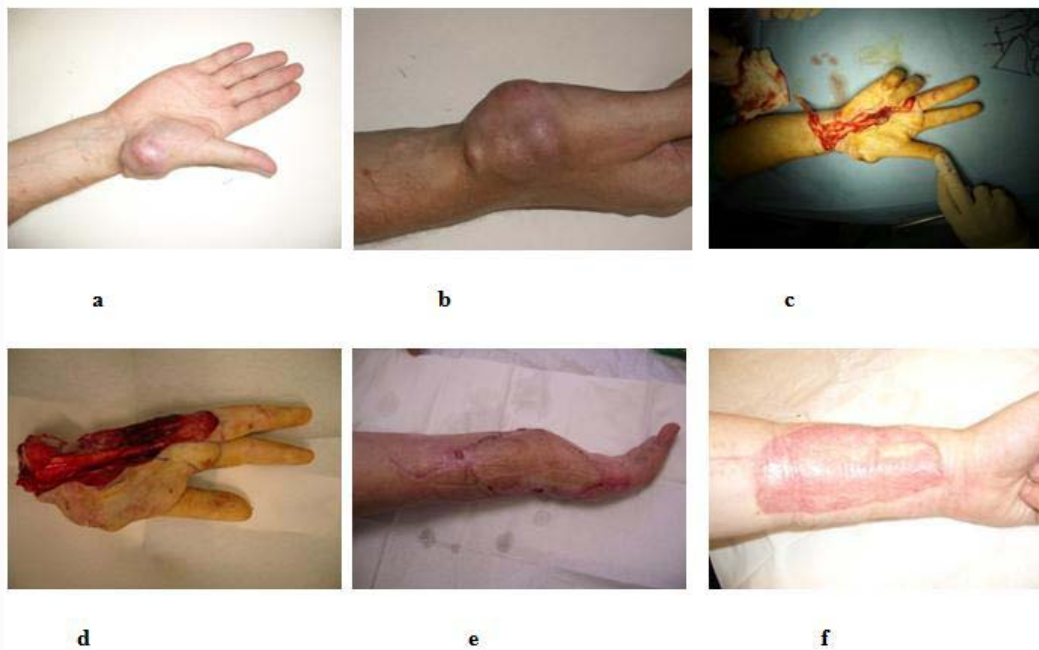
The tumor in this stage need treatment with wide local excision and limb salvage procedure is considered.

### Stage IB

The tumor in this stage requires wide local excision, and if there is any chance of residual tumour, the decision made between limb salvage and amputation.

### Stage IIA and IIB

These tumors are usually high grade and extra compartmental, also there is potential of skip metastasis. Guidelines explain if the tumour is responsive to chemotherapy, then it may be treated successfully with wide local excision and postoperative chemotherapy. The group of patients fall into this stage is real challenge to the Plastic Surgeon;



**Figure 1:** a) Malignant Schwannoma. b) Malignant Schwannoma. c) Rt Hand Partial Excision. d) Excision. e) Radial Free Forearm Flap. F) Lt Foreram Donor site.

where in the past radical amputation or disarticulation was the only option. We have been able to salvage the involved limb by using Plastic surgical reconstructive options.

### Stage III

The only hope to salvage the limb is where extremity STS is responsive to chemotherapy, the aggressive resection/amputation of the extremity STS performed where the tumour is not responsive to adjuvant therapy. However, in a study by Tierney JF showed the controversy of chemotherapy role in the treatment of STS [14,17].

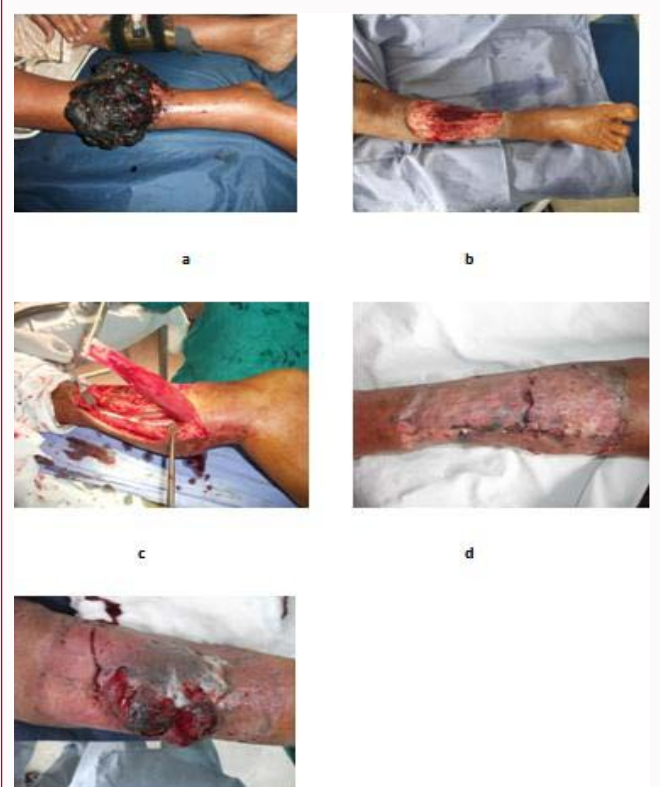There are more than 50 different histological types of STS described in the literature. The most common among 50 histological types is Undifferentiated Pleomorphic Sarcoma (UPS). World Health Organization (WHO) has recently described more than 100 subtypes of STS. Sarcoma originate from soft tissue in 80 % of cases and 20% arise in the bone [15,18,19].

The most common presentation age of the patient with STS over the age of 50, and are usually UPS or liposarcoma, however STS can present at any age. At younger age (less than 20 years) most common STS is either rhabdomyosarcoma or synovial sarcoma [14,20,21].

Optimal management of soft tissue sarcoma relies upon an appropriately performed biopsy, accurate diagnosis and staging, an effective surgical plan and execution, rational utilization of adjuvant therapies, and close surveillance following resection. This is best carried out at a tertiary care center with an experienced multidisciplinary team specializing in the care of sarcoma patients along with the plastic surgical reconstructive expertise to salvage the limb with the complex techniques of flap reconstruction.

Most commonly the patient having STS present clinically as enlarging lump or mass. The characteristic sign of STS are lump size more than 5 cm, lump deep to the deep fascia of the extremity and rapidly growing tumor [8-10,13,15].

The patient presenting with suspected sarcoma is evaluated with



**Figure 2:** a) Recurrent pleomorphic sarcoma. b) Wide local excision. c) Medial Gastrocnemius muscle flap. d) Closure with skin graft. e) Recurrence after six months.

detail history and thorough physical examination. The history of the patient should include duration of the lump, growth rate, and onset of pain, weakness or numbness of the limb, history of trauma, previous exposure to toxic carcinogens or radiation. Cancer in the family and history of smoking. The affected extremity should be examined for

the characteristics of the tumor, size of the tumor and consistency, tenderness, compartment of the limb and location of the tumor whether it is deep or superficial to the deep fascia of the limb. After complete examination of neurovascular status of the limb, regional lymph node examination of groin or axilla should be performed.

The specific investigation of lump includes incisional or excisional biopsy depending on the size of the tumor. Before embarking on to histology of the tumor, radiological investigation should be considered as previous surgery in the area may interfere the results of radiograph, Magnetic Resonance Imaging (MRI) or Computerized Tomography (CT) scan. X-rays of the involved extremity may show the presence or absence of soft tissue mass, bony involvement and microcalcification in the tumor.

To evaluate diagnostic features and staging of STS to plan the treatment, MRI is the mainstay of investigation. For instance, if MRI is not feasible or contraindicated then 3D reconstruction CT scan with or without intravenous contrast is advised. For staging purpose, when performing CT scan of the involved limb, the chest and abdomen should be scanned for evaluation of distant metastasis. Bony metastasis is rare in the extremity STS and bone scan is not routinely performed [9].

Dagan et al. [6] published a study on the role of radiotherapy in the treatment of extremity STS. This study explains the benefits of preoperative radiotherapy to control the disease. The author made conclusion whether the surgical excision is marginal, wide local excision or radical resection, radiation provide excellent local control of the involved limb. Postoperative radiotherapy provide almost similar effect to control the involved limb STS [22].

After having detail history, thorough physical examination and relevant investigation, the final treatment is planned according to the stage of the disease. The mainstay treatment of the extremity STS is a surgical resection. Surgical resection is performed according to the Enneking et al. [9] grading system: whether intralesional excision, marginal excision, wide local excision or radical excision. As a matter of fact, an intralesional margin is the type of incisional biopsy. Marginal excision preserves a cuff of 1 mm to 5 mm normal tissue with pseudocapsule or reactive zone. Wide local excision preserves 3 cm to 5 cm of normal tissue surrounding the tumor. Any of the limb muscle involved in the sarcoma, excision should perform of the tumor with 10 cm of the muscle if feasible, otherwise resection of the muscle should include origin and insertion of the muscle, the functional compartment preserve at least one functional muscle in the limb compartment and entire compartment is excised with radical margins if indicated [6,23].

The main indication of limb amputation depends upon the tumor size and extent. It is difficult to excise tumor with sufficient margins if neurovascular structure of the limb are involved and required to be sacrificed with the tumour excision, perhaps amputation may be the best option [24]. If the tumor involved single vessel of the limb, either single artery may be sacrificed with the tumor, or in certain conditions may be reconstructed with reverse vein graft to salvage the limb [25].

The author recommend to preserve the upper limb elbow and hand parts as much as possible to keep the hand functioning. A functional hand is superior to non functional prosthetic hand.

## Conclusion

This study corroborate evidence in support of reconstructive

plastic surgical procedures for the treatment of extremity STS to avoid limb amputation and less loss of function.

With the adjuvant radiation therapy and chemotherapy for high grade tumor, tumor more than 5 cm in size, incompletely excised tumor, the limb may be salvaged, where indicated [16,23]. The role of isolated limb perfusion for extremity STS is controversial due to the lack of randomized trials and limited availability of chemotherapeutic agent [26].

## References

1. Cormier JN, Pollock RE. Soft tissue sarcomas. *CA Cancer J Clin.* 2004;54(2):94-109.
2. Pollock RE, Maki RG. Introduction to Soft Tissue Sarcoma. In: Mahul B Amin, Stephen B Edge, Frederick L Greene, David R Byrd, Robert K Brookland, Mary Kay Washington, et al. editors. *AJCC Cancer Staging Manual.* Newyork: Springer International Publishing; 2017. p. 489.
3. Rosenberg SA, J Tepper, E Glatstein. The treatment of soft-tissue sarcomas of the extremities. Prospective randomized evaluations of (1) limb-sparing surgery plus radiation therapy compared with amputation and (2) the role of adjuvant chemotherapy. *Ann Surg.* 1982;196(3):305-15.
4. Zagars GK, Ballo MT, Pisters PW, Pollock RE, Patel SR, Benjamin RS, et al. Prognostic factors for patients with localized soft-tissue sarcoma treated with conservation surgery and radiation therapy: an analysis of 1225 patients. *Cancer.* 2003;97(10):2530-43.
5. O'Sullivan B, Davis AM, Turcotte R, Bell R, Catton C, Chabot P, et al. Preoperative versus postoperative radiotherapy in soft-tissue sarcoma of the limbs: a randomised trial. *Lancet.* 2002;359(9325):2235-41.
6. Dagan R, Indelicato DJ, McGee L, Morris CG, Kirwan JM, Knapik J, et al. The significance of a marginal excision after preoperative radiation therapy for soft tissue sarcoma of the extremity. *Cancer.* 2012;118(12):3199-207.
7. Abatzoglou S, Turcotte RE, Adoubali A, Isler MH, Roberge D. Local recurrence after initial multidisciplinary management of soft tissue sarcoma: is there a way out. *Clin Orthop Relat Res.* 2010;468(11):3012-8.
8. Novais EN, Demiralp B, Alderete J, Larson MC, Rose PS, Sim FH. Do surgical margin and local recurrence influence survival in soft tissue sarcomas? *Clin Orthop Relat Res.* 2010;468(11):3003-11.
9. Enneking WF, Spanier SS, Goodman MA. A system for the surgical staging of musculoskeletal sarcoma. *Clin Orthop Relat Res.* 1980;153:106-20.
10. Nystrom LM, Reimer NB, Reith JD, Dang L, Zlotecki RA, Scarborough MT, et al. Multidisciplinary Management of Soft Tissue Sarcoma. *Scientific World J.* 2013;2013:1-11.
11. Cates JMM. Performance Analysis of the American Joint Committee on Cancer 8th Edition Staging System for Retroperitoneal Sarcoma and Development of a New Staging Algorithm for Sarcoma-Specific Survival. *Ann Surg Oncol.* 2017;24(13):3880-7.
12. Italiano A, Di Mauro I, Rapp J, Pierron G, Auger N, Alberti L, et al. Clinical effect of molecular methods in sarcoma diagnosis (GENSARC): a prospective, multicentre, observational study. *Lancet Oncol.* 2016;17(4):532-8.
13. Yoon SS, Maki RG, Asare EA, Cooper K, Hornick JL, Lazar AJ, et al. Soft Tissue Sarcoma of the Trunk and Extremities. In: *AJCC Cancer Staging Manual*, 8<sup>th</sup> ed. Amin MB, editor. AJCC, Chicago. 2017. p. 507.
14. DM Hays. Rhabdomyosarcoma. *Clinical Orthopaedics and Related Research.* 1993;289:36-49.
15. *Musculoskeletal Tumors 2*, American Academy of Orthopaedic Surgeons, Rosemont, Ill, USA, 2007.
16. Gounder MM, Carvajal RD. *Soft Tissue Sarcoma Treatment Protocols.* Oncology. 2019.

17. Tierney JF. Adjuvant chemotherapy for localised resectable soft-tissue sarcoma of adults: meta-analysis of individual data. *Lancet*. 1997;350(9092):1647-54.
18. Fletcher CDM, Bridge JA, Hogendoorn PCW, Mertens F. World Health Organization Classification of tumors of soft tissue and bone, 4<sup>th</sup> ed. Lyon: IARC Press, France; 2013.
19. Siegel RL, Miller KD, Jemal A. Cancer statistics, 2019. *CA Cancer J Clin*. 2019;69(1):7-34.
20. Palmerini E, Staals EL, Alberghini M, Zanella L, Ferrari C, Benassi MS, et al. Synovial sarcoma: retrospective analysis of 250 patients treated at a single institution. *Cancer*. 2009;115(13):2988-98.
21. Pollock RE, Maki RG, Baldini EH, Hornick JL, Keedy VL, Lazar AJ, et al. Soft Tissue Sarcoma of the Retroperitoneum. 8<sup>th</sup> ed. In: Amin. *AJCC Cancer Staging Manual*, Chicago; 2017. p. 531.
22. Trovik CS. Local recurrence of soft tissue sarcoma: a scandinavian sarcoma group project." *Acta Orthop Scand Suppl*. 2001;72(300):1-31.
23. Cates MM, Cates JMM. Surgical resection margin classifications for high-grade pleomorphic soft tissue sarcomas of the extremity or trunk: definitions of adequate resection margins and recommendations for sampling margins from primary resection specimens. *Mod Pathol*. 2019;32(10):1421-33.
24. Ghert MA, Abudu A, Driver N, Davis AM, Griffin AM, Pearce D, et al. The indications for and the prognostic significance of amputation as the primary surgical procedure for localized soft tissue sarcoma of the extremity. *Ann Surg Oncol*. 2005;12(1):10-7.
25. Leggon RE, Huber TS, Scarborough MT. Limb salvage surgery with vascular reconstruction. *Clin Orthop Relat Res*. 2001;(387):207-16.
26. Jakob J, Hohenberger P. Role of isolated limb perfusion with recombinant human tumor necrosis factor  $\alpha$  and melphalan in locally advanced extremity soft tissue sarcoma. *Cancer*. 2016;122(17):2624-32.