



Induced Pigmentary Dispersion Syndrome with a Sulcus-Fixated Square-EDGE Hydrophobic Acrylic Intraocular Lens: Case Report

Aileen Walsh¹, César Motta² and Armando Stefano Crema^{2*}

¹Department of Ophthalmology, Federal University of Rio de Janeiro (UFRJ) - Rio de Janeiro (RJ), Brazil

²Department of Ophthalmology, Federal University of São Paulo (Unifesp) - São Paulo (SP), Brazil

Abstract

A 46-year-old white male patient had right eye cataract surgery 3 years ago with a hydrophobic single-piece intra ocular lens (IOL) (AcrySof SN60WF, Alcon labs). Since then he reported recurrent episodes of blurred vision, severe ocular pain and headache. The secondary dispersion syndrome with secondary pigmentary glaucoma was controlled by a 3-piece hydrophobic acrylic IOL exchange (AcrySof MA60AC, Alcon labs). The episodes of blurred vision and recurrent iritis disappeared completely and the IOP returned to normal levels without therapy.

Keywords: Hydrophobic IOL; Pigment dispersion syndrome; Secondary glaucoma

Introduction

Implantation of a hydrophobic acrylic single-piece intraocular lens (IOL) (AcrySofAlcon labs) has become a routine practice among many surgeons, and several studies describe advantages of symmetric in-the-bag fixation of these IOLs. Posterior iris chafing by the loop or the optic portion of these IOLs, when sulcus fixated, may cause pigment dispersion related complications. This situation is sometimes missed by surgeons and diagnosis is not made.

Case Presentation

A 46-year-old white male patient had right eye cataract surgery 3 years ago with an AcrySof SN60WF IOL implant at another clinic. Since then he reported episodes of blurred vision, severe ocular pain and headache (which were incompatible with his labor). He had already visited several ophthalmologists, had several complimentary tests performed (ANA, VDRL, FTA Abs, X-ray, etc.), and had tried numerous treatments, include ingoral valacyclovir during 14 days for a hypothetic herpetic uveitis diagnosis. The fellow eye was normal with no ocular findings or surgeries. At the time he was using prednisolone acetate 1.2 mg QID, brimonidine tartrate and timolol maleate bid in the right eye. On examination BCDVA OD was 20/25 (-0.75sph -0.75cyl 25°); IOP of 40 mmHg (2 pm); biomicroscopy showed severe flare and Tyndall in the anterior chamber and nasal iris Trans illumination defect (Figure 1A). The gonioscopy showed a significant amount of pigments in the trabecular meshwork, open angle and absence of goniosynechia. A nasal decentration of the single-piece IOL was observed after pupil dilation; both haptics were outside the capsular bag in the sulcus (Figures 1B and 1C). The posterior capsule was intact and funduscopy showed a normal optic disc. Prednisolone acetate 10 mg therapy every 2 h was prescribed and intra-ocular pressure eye drops

OPEN ACCESS

*Correspondence:

Armando Stefano Crema, Department of Ophthalmology, Federal University of São Paulo (Unifesp) - São Paulo (SP), Brazil,

E-mail: acrema@openlink.com.br

Received Date: 07 Apr 2017

Accepted Date: 26 Jun 2017

Published Date: 06 Jul 2017

Citation:

Walsh A, Motta C, Crema AS. Induced Pigmentary Dispersion Syndrome with a Sulcus-Fixated Square-EDGE Hydrophobic Acrylic Intraocular Lens: Case Report. *Clin Surg.* 2017; 2: 1545.

Copyright © 2017 Crema AS. This is an open access article distributed under the Creative Commons Attribution License, which permits unrestricted use, distribution, and reproduction in any medium, provided the original work is properly cited.



Figure 1A: Anterior chamber and nasal iris transillumination defect.




Figure 1B: Capsular bag in the sulcus.

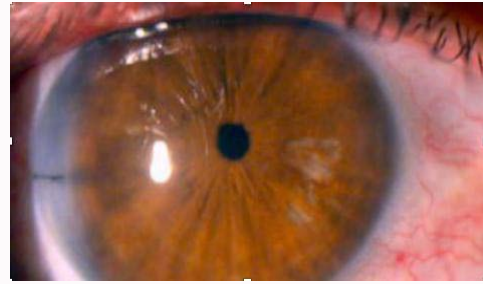


Figure 2A: Patient had no complaints in the first postoperative day.

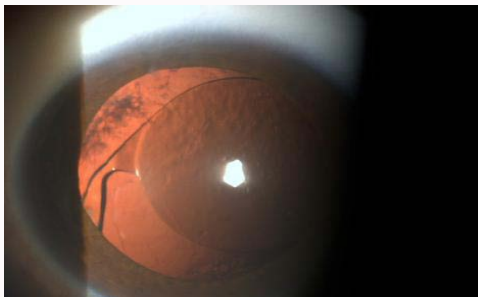


Figure 1C: Capsular bag in the sulcus.

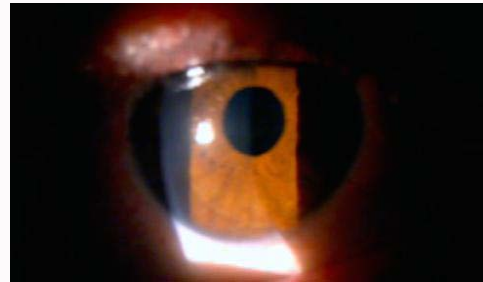


Figure 2B: No inflammatory reaction and the IOP was 12 mmHg without use of medication.

were maintained. Five days after, the IOP was 24 mmHg and only a low amount of thyndall was observed at biomicroscopy. We then decided for a 3-piece hydrophobic acrylic IOL (AcrySof MA60AC, Alcon labs) exchange.

Under topical anesthesia, a 3.75 mm clear corneal incision was made, dispersive OVD (Viscoat) was injected into the anterior chamber and under the decentered IOL, displacing it to the anterior chamber, where it was folded and then removed. The 3-piece IOL was injected and placed in the sulcus, and miosis was obtained with myochol. The incision was closed with a single 10-0 nylon stich. UCDVA improved to 20/25, there was no anterior chamber reaction, the IOP was 14 mmHg, and the patient had no complaints in the first postoperative day (Figure 2A). Fifteen days after UCDVA improved to 20/20, there was no inflammatory reaction and the IOP was 12 mmHg without use of medication (Figure 2B). The patient was pleased with the outcome.

Discussion

Pigmentary dispersion with nasal iris defect leading to intense recurrent anterior chamber reaction, increased IOP, blurred vision and intolerable ocular pain were observed in this case with sulcus fixated implantation of a single-piece hydrophobic acrylic IOL. Similar cases of pigmentary dispersion associated with sulcus-fixated IOLs have been described. Single-piece AcrySof lenses have a square optic and haptic edges and they are planar with no posterior vault. Due to these features these IOLs when implanted in the sulcus can lead to mechanical friction between the IOL and the posterior layer of the iris causing pigmentary dispersion syndrome as well as secondary pigmentary glaucoma. In our case, biomicroscopy showed the presence of cells in anterior chamber and with Tran's illumination

an iris defect, and gonioscopy a higher amount of pigment in the trabecular meshwork of the right eye than in the normal fellow phakic eye. Pathological findings of eyes with asymmetric or sulcus-fixated hydrophobic acrylic IOLs with square anterior and posterior optic and haptic edges include pigmentary dispersion within the eye and on the IOL surface, iris trans illumination defects, iris changes including vacuolization/disruption/loss of the pigmented layer, iris thinning and iris atrophy [1-3]. Removing the entire IOL and exchanging it with a 3-piece IOL with larger overall length and with thin angulated loops that keep the optic away from the iris, allows a sulcus fixation implant [3]. This design ensures that contact of the lens with the posterior layer of the iris doesn't occur [4]. In conclusion, single piece AcrySof IOLs are designed for in the bag implantation only, and surgeons have to ensure that the haptics are correctly implanted in the capsular bag, especially in patients with small pupils.

References

1. Vizzeri G, Weinreb RN. Cataract surgery and glaucoma. *Curr Opin Ophthalmol.* 2010;21(1):20-4.
2. Trindade F, Werner L, Werner L. Lentes intra oculares para incisãope quena In:Rezende F (Ed) *Cirurgia de Catarata.* Rio de Janeiro: CulturaMédica. 2000;260-4.
3. Kirk K, Werner L, Jaber R, Strenk S, Strenk L, Mamalis N. Pathological Assessment of complications with asymmetric or sulcus fixation of square-edge hydrophobic acrylic intraocular lenses. *Ophthalmology.* 2012;119(5):907-13.
4. Le Boyer RM, Werner L, Snyder ME, Mamalis N, Riemann CD, Augsberger JJ. Acute haptic-induced ciliary sulcus irritation associated with single-piece AcrySof intraocular lenses. *J Cataract Refract Surg.* 2005;31(7):1421-7.