



Emergency Progressive Tracheal Dilation with Conventional Tubes before Stenting in Thyroid Mass: A Case Report

Alessandro Crepaldi^{1*}, Enrico Giustiniano², Alberto Testori¹, Nadia Fusilli², Marco Alloisio¹, Ugo Cioffi³ and Giorgio Maria Ferraroli¹

¹Department of Thoracic and General Surgery, Istituto Clinico Humanitas, Rozzano (Milano), Italy

²Department of Anesthesia and Intensive Care Unit, Istituto Clinico Humanitas, Rozzano (Milano), Italy

³Department of Surgery, University of Milan, Milano, Italy

Abstract

An 80-year-old female patient presented to the emergency room for dyspnea and “tirage” caused by massive thyroid cancer. In these cases tracheal dilation by rigid bronchoscopy is the treatment of choice. Before the procedure we performed progressive dilatation with repeated intubations using conventional tube with increased diameters. No adverse events occurred. She was discharged from ICU to the ward on the day after the operation. This procedure allows being more confident in terms of patient ventilation, less trauma to the stenotic tracheal mucosa, less ICU stay, easy material availability and less cost for public health.

Keywords: Tracheal stenosis; Thyroid tumors; Rigid bronchoscopy; Emergency intubation

Introduction

Tracheal stenosis due to invasion or compression by thyroid tumor is usually treated by dilation and stenting using rigid bronchoscope, when surgical procedures are not indicated. In very rare cases (emergency setting with respiratory failure, severe distortion of the trachea), rigid endoscopic intubation could be at high risk or even not feasible. We describe a technique to progressively dilate in emergency setting a severe tracheal stenosis using conventional tubes.

This procedure allows sufficient dilation of the stenotic trachea, while maintaining adequate ventilation of the patient. It then allows a safe insertion of a stent via rigid bronchoscopy.

Case Presentation

An 80 year-old woman was admitted to the Emergency-Room of our Hospital for dyspnea and “tirage” due to a bulky cervical mass. Few days before she underwent a neck and chest MRI that showed a neoplastic thyroid mass deforming and invading the upper trachea for a 3 cm length, associated with pulmonary lesions, suspected for metastasis (Figure 1). The patient was dyspneic with peripheral desaturation, blood hypertension and tachycardia. She was immediately transferred to the operatory theatre to dilate the tracheal stenosis and insert a stent in Rigid Bronchoscopy (RB). Tracheostomy was not feasible for the presence of the cervical tumor. In our Institution, rigid endoscopy is performed assuring a spontaneous breathing during total intra-venous anesthesia. In this case, we expected a complex performance of RB and a coexisting difficult airways management. Hence we adopted a type of sedation with a more limited risk of respiratory function worsening: pre-medication with atropine (0.5 mg i.m.) and administration of midazolam (2 mg i.v.) and ketamine (50 mg i.v.). When the patient reached a sufficient level of sedation, we tried to introduce the rigid bronchoscope through the vocal cords, but the maneuver resulted particularly difficult. In the meanwhile the patient became quickly hypoxic (SatO₂ 35%) and cyanotic. After increasing bradycardia, asystole occurred despite the administration of atropine (0.5 mg i.v.). Cardio-pulmonary resuscitation started and the patient was intubated with an orotracheal tube (#5.5 Hi-Contours, Mallinkrodt™). She was ventilated with FiO₂ 100% until saturation and cardiac function were restored. External thoracic compression and epinephrine (1 mg i.v.) was needed. Effective circulation was restored in 2 min, with normal and light-reactive pupils. After resuscitation, sedation was maintained with ketamine and propofol. After that, we decided to try to dilate the trachea

OPEN ACCESS

*Correspondence:

Alessandro Crepaldi, Department of Thoracic and General Surgery, Istituto Clinico Humanitas, Rozzano (Milano), Italy, Tel: +39 02 82247736; E-mail: alessandro.crepaldi@humanitas.it

Received Date: 10 Jul 2018

Accepted Date: 27 Jul 2018

Published Date: 31 Jul 2018

Citation:

Crepaldi A, Giustiniano E, Testori A, Fusilli N, Alloisio M, Cioffi U, et al. Emergency Progressive Tracheal Dilation with Conventional Tubes before Stenting in Thyroid Mass: A Case Report. *Clin Surg.* 2018; 3: 2057

Copyright © 2018 Alessandro Crepaldi. This is an open access article distributed under the Creative Commons Attribution License, which permits unrestricted use, distribution, and reproduction in any medium, provided the original work is properly cited.

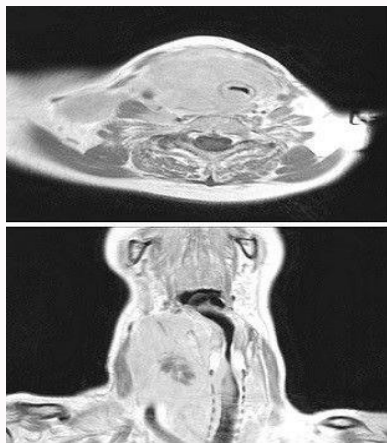


Figure 1: MRI that shows severe compression and distortion of the upper trachea.

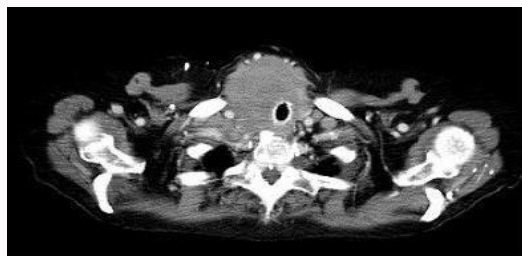

Figure 2: CT-scan after insertion of tracheal stent.

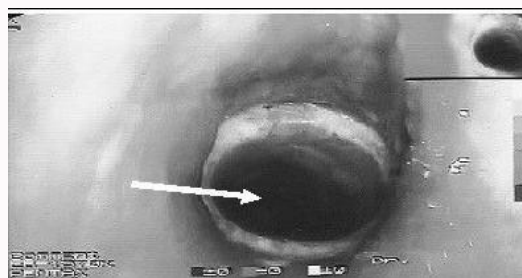


Figure 3: Bronchoscopic image of the stent at the level of the proximal third of the trachea.

with repeated intubation using progressive bigger conventional tubes (Hi-Contour, Mallinkrodt™), reaching an adequate caliber to allow intubation with rigid bronchoscope. Therefore we substituted the small orotracheal tube repeatedly with other larger tubes sliding them on a Frova catheter. After insertion of #8.0 orotracheal tubes, the patient was extubated. The surgeon introduced the rigid bronchoscope and bypassed the tracheal stenosis with a silicone stent (Novatech, 14 × 40, La Chiotat, Marseille, France) (Figure 2, 3).

During the procedure (lasted 20 min) the patient did not experienced any adverse event. Despite patient's spontaneous

breathing, she was manually assisted during the operation through the rigid bronchoscope when needed. Hemodynamics always stayed in a normal setting. At the end of the procedure, blood gas-analysis showed pH 7.36, pCO₂ 47 mmHg and pO₂ 133 mmHg, SatO₂ 98%, normal serum lactate and base excess. At the completion of the procedure, the patient was re-intubated with an orotracheal tube #8. Sedation was gradually stopped. When vital signs allowed, she was extubated and admitted to our ICU for over-night surveillance. No adverse events occurred. She was discharged from ICU to the ward on the day after the operation. She was dismissed from the Hospital after 5 days. The histological examination showed a great cells non-Hodgkin B-lymphoma of the thyroid gland. The patient started a chemotherapeutic treatment and she is still alive after 2 years from the operation.

Discussion

In emergency event, the anesthesiologists should take valuable treatment to ensure ventilation. In this case we performed a procedure before the rigid bronchoscopy to enable us to take prompt action in case of sudden and critical changes. We consider this technique may be safe, easy to perform with low cost. It could be useful in treating tracheal stenosis in emergency setting, particularly when there is a severe distortion that could make any endoscopic treatment particularly challenging.

References

1. Nishijima Y, Takahashi H, Taguchi N, Naito H. A newly devised endotracheal tube for patients with narrowed trachea. *Masui*. 1993;42:455-7.
2. Lacoste L, Gineste D, Karayan J, Montaz N, Lehuéde MS, Girault M, et al. Airway complications in thyroid surgery. *Ann Otol Rhinol Laryngol*. 1993;102(6):441-6.
3. Loftus PA, Ow TJ, Siegel B, Tassler AB, Smith RV, Schiff BA. Risk Factors for Perioperative Airway Difficulty and Evaluation of Intubation Approaches among Patients With Benign Goiter. *Ann Otol Rhinol Laryngol*. 2014;123(4):279-85.
4. Yamaguchi K, Fujimoto K, Koide Y, Kurahashi K. Safe induction of anesthesia in 3 patients with severe tracheal stenosis caused by thyroid cancer. *Masui*. 2013;62(1):78-82.
5. Tsutsui H, Kubota M, Yamada M, Suzuki A, Usuda J, Shibuya H, et al. Airway stenting for the treatment of laryngotracheal stenosis secondary to thyroid cancer. *Respirology*. 2008;13(5):632-8.
6. Han YH, Jung BH, Kwon JS, Lim J. Successful Treatment of Tracheal Invasion Caused by Thyroid Cancer using Endotracheal Tube Balloon Inflation under Flexible Bronchoscopic Guidance. *Tuberc Respir Dis*. 2014;77:215-8.
7. Lee J, Won JH, Kim HC, Soh EY. Emergency dilation by self-expandable tracheal stent for upper airway obstruction in a patient with a giant primary thyroid lymphoma. *Thyroid*. 2009;19(2):193-5.