



DCIS Breast Arising in a Fibroadenoma- Case Report of a Rare Condition

Gollapalli V*, Bibi A K Shah S and Gilchrist B

Department of Surgery, Bronx-Lebanon Hospital, USA

Abstract

Fibroadenoma (FA) is a type of benign tumor that occurs in young women below the age of 35 years old. The incidence of carcinoma arising with FA is rare with range of 0.002 to 0.125%. Most cases are detected at an early stage, cases of locally advanced carcinoma with distant metastasis have been published. We report a case of DCIS with microinvasion arising within Fibroadenoma which was being followed for 9 years.

Keywords: Breast cancer; Fibroadenoma; Carcinoma *in situ*

Case Presentation

This is a 43 year female who was being followed for an image detected lesion (fibroadenoma) in the right breast upper outer quadrant, since age 34 (9 years ago). She had no family history of breast cancer. Imaging with mammogram and ultrasound which showed a vague lesion in a dense breast tissue on right side. Her serial mammogram was inconclusive BI RADS 0 due to density of breast (Figure 1). Serial ultrasound showed a hypoechoic lesion of less than 2 cm lesion between 8 to 9 'o'clock position with a calcification focus (Figure 2-5). Each time it was categorized as BIRADS 3 and required closed follow up. After 9 years of follow up, mammogram showed focus of polymorphic micro calcifications warranting biopsy (Figure 6-9). Ultrasound guided biopsy showed ductal carcinoma in situ, with areas of micro invasion. She underwent needle localized

OPEN ACCESS

*Correspondence:

Gollapalli V, Department of Surgery,
Bronx-Lebanon Hospital, 1650 Selwyn
Avenue, Suite 4A, Bronx, New York
10457, USA, Tel: 9173247635; Fax:
718-960-1370;

E-mail: wwinod@hotmail.com

Received Date: 28 Nov 2016

Accepted Date: 03 Feb 2017

Published Date: 15 Feb 2017

Citation:

Gollapalli V, Bibi A K Shah S,
Gilchrist B. DCIS Breast Arising in a
Fibroadenoma- Case Report of a Rare
Condition. *Clin Surg.* 2017; 2: 1312.

Copyright © 2017 Gollapalli V. This is an open access article distributed under the Creative Commons Attribution License, which permits unrestricted use, distribution, and reproduction in any medium, provided the original work is properly cited.

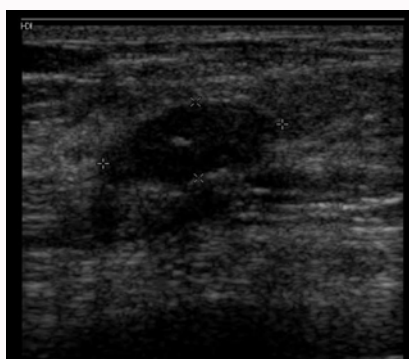


Figure 1: Density of Breast.

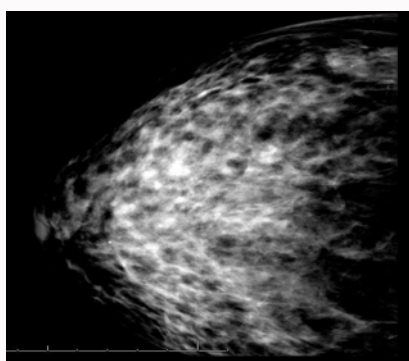


Figure 2: Hypoechoic lesion.

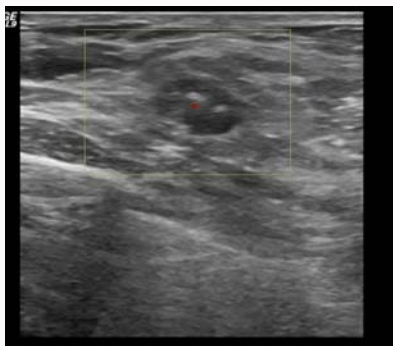


Figure 3: Hypoechoic lesion.

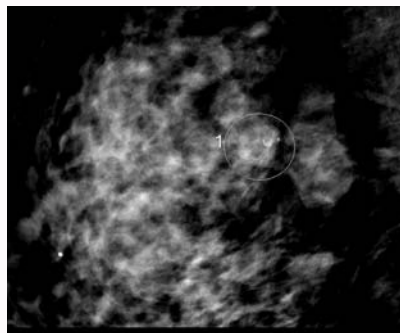


Figure 6: Polymorphic micro calcifications.

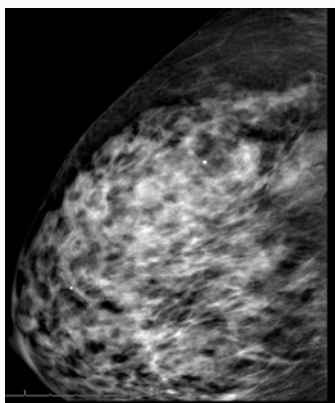


Figure 4: Hypoechoic lesion.

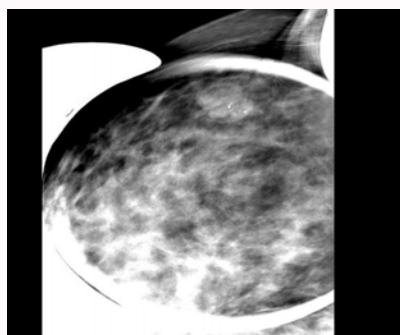


Figure 7: Polymorphic micro calcifications.

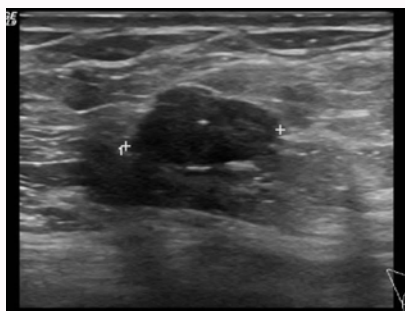


Figure 5: Hypoechoic lesion.

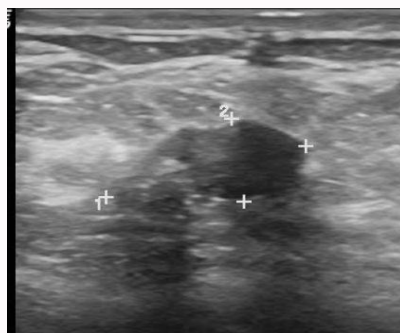


Figure 8: Polymorphic micro calcifications.

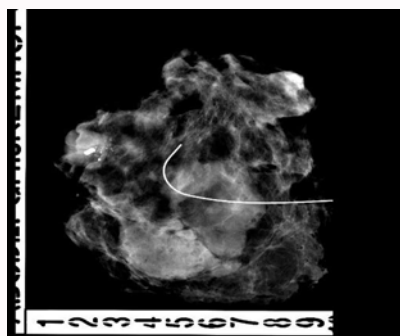


Figure 9: Polymorphic micro calcifications.

partial mastectomy and Sentinel lymph node biopsy. Final pathology showed in-situ ductal carcinoma arising from hyalinized FA with micro invasion. The size was 0.5 cm (pT1mic) and lymph node negative (pN0). Tumor was estrogen and progesterone receptor positive and Her2 neu receptor negative. All margins were negative. She is currently undergoing radiation therapy followed by hormonal therapy. The patient was followed up every 3 months, and at the last follow-up examination in June 2016, the patient exhibited no signs of recurrence.

Discussion

Fibroadenoma (FA) is a common type of benign tumor that occurs in younger women below the age of 35 years old, with a reported incidence rate of 7–13% in female individuals. It may occur at any age; however, the peak age of incidence is in the second and third decade of life. They occur asymptotically in 25% of all patients. The FA can be stimulated by estrogen, progesterone, pregnancy and lactation,

and may undergo atrophy during menopause [1,2]. Furthermore, FA is a biphasic tumor composed of stromal and epithelial components, and can be effectively treated by local excision [3].

The majority FAs is clinically identifiable; however, 25% of cases are non-palpable and, thus, require mammography and/or

ultrasonography (US) for diagnosis [4-6]. Currently, the therapeutic methods used for breast cancer include surgery, chemotherapy, radiotherapy, endocrine therapy and targeted therapy [3]. The incidence of carcinoma arising with FA is rare with range of 0.002 to 0.125%. Previous studies have reported that fibroadenoma can evolve into different types of malignancy, such as lobular intraepithelial neoplasia, lobular carcinoma *in situ*, malignant phyllodes tumors and microinvasive lobular carcinoma [4,6-9].

According to its clinicopathological presentation, FA can be divided into simple and complex FA. Complex FA is characterized by cysts, sclerosing adenosis, epithelial calcification or papillary apocrine change [10-12]. Carcinoma arising within a fibroadenoma is a rare with an incidence rate of 0.1-0.3% in a screened population (10) and unique subtype of mammary cancer, which was reported by Buzanowski-Konakry et al. [7] in 1975. To date, < 130 cases have been reported in the worldwide literature.

Therefore, histological diagnosis is typically unexpected [1,8,9,13,14]. The mean age of patients with carcinoma in FA has been reported as 42-44 years, ~20 years subsequent to the peak age of occurrence of FA [15,16]. Our patient was in this 40's age group. Two-thirds of carcinomas within FA are lobular, and one-third are ductal or mixed ductal and lobular, with the frequency of LCIS and ductal carcinoma *in situ* almost equal [2,15]. Carcinoma is diagnosed as arising within FA if: 1) The carcinoma is entirely encased within the FA; or 2) if the carcinoma is only focally involved with the adjacent breast tissue [16]. The case presented in the present study met the first criterion.

FA is typically considered to be a type of benign lesion and requires careful observation. However, data regarding whether FA is a risk factor for carcinoma is inconsistent [17]. A number of studies have provided evidence of the association between the excised FA and carcinoma. The relative risk of developing breast cancer following surgically excised FA appears to depend on the histological characteristics of FA and the state of the breast parenchyma [18-24].

The present case showed that FAs containing foci of carcinoma *in situ* can be indistinguishable from benign lesions following imaging, therefore, despite the incidence of carcinoma within FA is estimated at 0.1-0.3%, it should be considered a long-term risk factor for invasive breast cancer. The present describes a case of DCIS arising within an FA and conducts a review of the relevant literature [25-30].

FA is considered to be an aberration of normal breast development [19] and the majority that occur in younger females may resolve or reduce in size without intervention [6,20]. Although malignancy in FA is rare it may be difficult to predict malignant transformation in an FA, as the clinical and radiological signs may be masked [2,21]. There is a general consensus that the management of FA depends on the age of the patient, the nature of the lesion, the family history of breast or ovary carcinoma, or any data of proliferative changes in the breasts from previous biopsies [6,20]. For example, previous studies have proposed a conservative therapeutic strategy for FA in patients younger than a certain age. However, the threshold ages proposed or conservative treatments are inconsistent, and have been reported as 25, 35 and 45 years [22-25].

If the lesion increases in size, excision is immediately performed. However, if the lesion is regressive, follow up should be continued until the regression is complete. If the lesion does not completely regress, or stabilizes by the age of 35 years, a lumpectomy is suggested.

For females aged >35 years, surgery is recommended when the lesion is stable or increases in size after a 6- to 12-month follow-up period. Additionally, excision is recommended for any complex FA. For patients with a family history of breast and/or ovarian cancer, surgery is more actively advised. The treatment for DCIS arising within fibroadenoma is not clearly defined. DCIS is treated by surgical excision, followed by radiotherapy as part of breast conserving treatment, and/or endocrine therapy.

The aggressiveness, morbidity and mortality are not clear. Presence of carcinoma could also be a sign of the deficiency related to the screening system. As most of these patients are young and have dense breast that might preclude detection of these lesions. Ultrasound is operator dependent close follow up may not be as accurate as possible. Hence suggest early MRI of breast as an option.

Conclusion

In conclusion, the present case was reported to increase awareness that FA in the middle and older age group can harbor cancer, early intervention in this age group is suggested. Complex FA has a higher risk. High degree of suspicion is needed, as there are limitations in screening, which adds to the problem of delayed diagnosis.

References

- Kuijper A, Mommers EC, van der Wall E, van Diest PJ. Histopathology of the fibroadenomas of the breast. *Am J Clin Pathol.* 2001; 115: 736-742.
- Kuijper A, Preisler-Adams SS, Rahusen FD, Gille JJ, van der Wall E, van Diest PJ. Multiple fibroadenomas harboring carcinoma *in situ* in a woman with a family history of breast/ovarian cancer. *J Clin Pathol.* 2002; 55: 795-797.
- Azzopardi JG Ahmed, Mills RR. Problems in breast pathology. *Major Probl Pathol.* 1979; 11: 325-328.
- Drukker BH. Breast disease: a primer on diagnosis and management. *Int J Fertil Womens Med.* 1997; 42: 278-287.
- Dupont WD, Page DL, Parl FF, Vnencak-Jones CL, Plummer WD Jr, Rados MS, et al. Long-term risk of breast cancer in women with fibroadenoma. *N Engl J Med.* 1994; 331: 10-15.
- Greenberg R, Skornick Y, Kaplan O. Management of breast fibroadenomas. *J Gen Intern Med.* 1998; 13: 640-645.
- Buzanowski-Konakry K, Harrison EG Jr, Payne WS. Lobular carcinoma arising in fibroadenomas of the breast. *Cancer.* 1975; 35: 450-456.
- Iyengar KR, Peh SC, Yip CH, Vijayanathan A. Infiltrating duct carcinoma within a fibroadenoma. *Indian J Cancer.* 2009; 46: 244-246.
- Abe H, Hanasawa K, Naitoh H, Endo Y, Tani T, Kushima R. Invasive ductal carcinoma within a fibroadenoma of the breast. *Int J Clin Oncol.* 2004; 9: 334-338.
- Lakhani SR, Ellis LO, Schnitt SJ, Tan PH, van de Vijver. WHO classification of tumours of the breast. In: Lakhani SR, Schnitt SJ, Malley FO, van de Vijver MJ, Simpson PT, Palacios J, editors. *Lobular neoplasia.* IARC Press; Lyon. 2012; 77-80.
- Dixon JM, Mansel RE. ABC of breast diseases. Congenital problems and aberrations of normal breast development and involution. *BMJ.* 1994; 309: 797-800.
- Tissier F, De Roquancourt A, Astier B, Espie M, Clot P, Marty M, et al. Carcinoma arising within mammary fibroadenomas. A study of six patients. *Ann Pathol.* 2000; 20: 110-114.
- Sklair-Levy M, Sella T, Alweiss T, Craciun I, Libson E, Mally B. Incidence and management of complex fibroadenomas. *AJR Am J Roentgenol.* 2008; 190: 214-218.

14. Netto D, Satchidanand SK, Gaeta JF. Carcinomas arising in fibroadenomas: a report of two cases and a review of literature. *J Surg Oncol.* 1980; 13: 367-372.
15. Diaz NM, Palmer JO, McDivitt RW. Carcinoma arising within fibroadenomas of the breast. A clinicopathologic study of 105 patients. *Am J Clin Pathol.* 1991; 95: 614-622.
16. Pick PW, Iossifides IA. Occurrence of breast carcinoma within a fibroadenoma. A review. *Arch Pathol Lab Med.* 1984; 108: 590-594.
17. Dent DM, Cant PJ. Fibroadenoma. *World J Surg.* 1989; 13: 706-710.
18. McDivitt RW, Stevens JA, Lee NC, Wingo PA, Rubin GL, Gersell D. Histologic types of benign breast disease and the risk for breast cancer. The Cancer and Steroid Hormone Study Group. *Cancer.* 1992; 69: 1408-1414.
19. Hughes LE, Mansel RE, Webster DJ. Aberrations of normal development and involution (ANDI): a new perspective on pathogenesis and nomenclature of benign breast disorders. *Lancet.* 1987; 2: 1316-1319.
20. Carty NJ, Carter C, Rubin C, Ravichandran D, Royle GT, Taylor I. Management of fibroadenoma of the breast. *Ann R Coll Surg Engl.* 1995; 77: 127-130.
21. Goldman RL, Friedman NB. Carcinoma of the breast arising in fibroadenoma, with emphasis on lobular carcinoma. A clinicopathologic study. *Cancer.* 1969; 23: 544-550.
22. Cant PJ, Madden MV, Close PM, Learmonth GM, Hacking EA, Dent DM. Case for conservative management of selected fibroadenomas of the breast. *Br J Surg.* 1987; 74: 857-859.
23. Sainsbury JR, Nicholson S, Needham GK, Wadehra V, Farndon JR. Natural history of the benign breast lump. *Br J Surg.* 1988; 75: 1080-1082.
24. Wilkinson S, Anderson TJ, Rifkind E, Chetty U, Forrest AP. Fibroadenoma of the breast: a follow-up of conservative management. *Br J Surg.* 1989; 76: 390-391.
25. Dixon JM, Dobie V, Lamb J, Walsh JS, Chetty U. Assessment of the acceptability of conservative management of fibroadenoma of the breast. *Br J Surg.* 1996; 83: 264-265.
26. Fukuda M, Nagao K, Nishimura R, Matsuda M, Baba K, Ueno Y, et al. Carcinoma arising in fibroadenoma of the breast-a case report and review of the literature. *Jpn J Surg.* 1989; 19: 593-596.
27. Yoshida Y, Takaoka M, Fukumoto M. Carcinoma arising in fibroadenoma: Case report and review of the world literature. *J Surg Oncol.* 1985; 29: 132-140.
28. Tanaka A, Hirano M, Sakai Y, Ichikawa T, Nitta N, Henmy K. Fibroadenoma, mastopathy, intraductal papilloma: Relationship to carcinoma-a case report of carcinoma of the breast arising in fibroadenoma. *Nihon Geka Hokan.* 1983; 52: 232-243.
29. El-Wakeel H, Umpleby HC. Systematic review of fibroadenoma as a risk factor for breast cancer. *Breast.* 2003; 12: 302-307.
30. Wu YT, Chen ST, Chen CJ, Kuo YL, Tseng LM, Chen DR, et al. Breast cancer arising within fibroadenoma: collective analysis of case reports in the literature and hints on treatment policy. *World J Surg Oncol.* 2014; 12: 335.