



Bilateral Bucket-Handle of the Medial Meniscus: Presentation of Two Cases and Literature Review

Cerciello S^{1,2,3*}, Mercurio M⁴, Proietti L¹, Santagada A³, Ciolli G³ and Corona K⁵

¹Department of Orthopedic and Trauma Surgery, "Villa Betania" Clinic, Italy

²Marrelli Hospital, Crotone, Italy

³Department of Orthopedics, A Gemelli University Hospital Foundation IRCCS, Catholic University, Italy

⁴Department of Orthopedic and Trauma Surgery, "Magna Græcia" University, "Mater Domini" University Hospital, Italy

⁵Department of Medicine and Health Sciences "Vincenzo Tiberio", University of Molise, Italy

Abstract

Bucket handle lesions usually follow traumas in active adults. Bilateral cases are uncommon and may be associated with anatomic abnormalities. Aims of the present case report are to present two cases of non-simultaneous bucket handle lesion of the medial meniscus and to analyze the current available literature on the topic.

Keywords: Bucket handle; Bilateral; Medial meniscus; Arthroscopy; Trauma

Introduction

Bucket-handle meniscal tears are relatively common injuries of young athletes. They account for up to 26% of all meniscal tears, usually occurring after trauma, mostly affecting the medial meniscus due to its anatomy and biomechanical characteristics [1]. Although bucket-handle meniscal tears are usually unilateral [2], a few previous descriptions of bilateral involvement have been reported. Aims of the present case report are to present two cases of non-simultaneous bucket handle lesion of the medial meniscus and to analyze the current available literature on the topic.

OPEN ACCESS

*Correspondence:

Simone Cerciello, Department of Orthopedic and Trauma Surgery, "Villa Betania" Clinic, Casa di Cura Villa Betania, Via Pio Quarto 42, Rome, Italy,

E-mail: Simone.cerciello@me.com

Received Date: 06 Jan 2021

Accepted Date: 03 Feb 2021

Published Date: 11 Feb 2021

Citation:

Cerciello S, Mercurio M, Proietti L, Santagada A, Ciolli G, Corona K. Bilateral Bucket-Handle of the Medial Meniscus: Presentation of Two Cases and Literature Review. *Clin Surg.* 2021; 6: 3061.

Copyright © 2021 Cerciello S. This is an open access article distributed under the Creative Commons Attribution License, which permits unrestricted use, distribution, and reproduction in any medium, provided the original work is properly cited.

Case Series

Case 1

In November 2011, a 35-year-old woman was admitted to our institution complaining of acute pain and loss of extension on her right knee following a jump in a domestic setting. Physical examination revealed a normally aligned knee with minimal joint effusion. Knee flexion was complete with a loss of extension of 20° and positive Rising Moon sign [3]. Ligaments, patellar facets and the lateral compartment were negative. Magnetic Resonance Imaging (MRI) showed a displaced bucket-handle of the medial meniscus, as defined by an absent bow tie sign, a double posterior cruciate ligament sign, the anterior flipped fragment sign, and a fragment displaced into the intercondylar notch (Figure 1) [4-8]. A knee arthroscopy confirmed the displaced bucket handle of the medial meniscus. There was no evidence of medial meniscus abnormalities in terms of size and anatomy. Cartilage was normal as well as the lateral meniscus and ligaments of the central pivot. A partial medial meniscectomy (meniscal suture was not proposed) was performed. Standard rehabilitation protocol was observed with complete functional recovery.

The patient was readmitted in April 2017, complaining of acute pain on her left knee following a hyperflexion movement in a domestic setting. Physical examination revealed a minimal loss of extension of 5° and a positive Rising Moon sign. MRI assessment showed a displaced bucket-handle of the medial meniscus (Figure 1). Arthroscopy confirmed a meniscal tear in the red-white zone. There was no evidence of medial meniscus abnormalities. Grade-2 chondral damage according to the Outerbridge classification [9,10] was observed on the medial condyle. Both the central pivot and the lateral meniscus were intact. As the patient refused to undergo a meniscal suture, a partial medial meniscectomy and debridement of the cartilage lesion were performed. At the latest available examination (July 2020), the patient showed completed pain relief and full ROM and functional recovery.

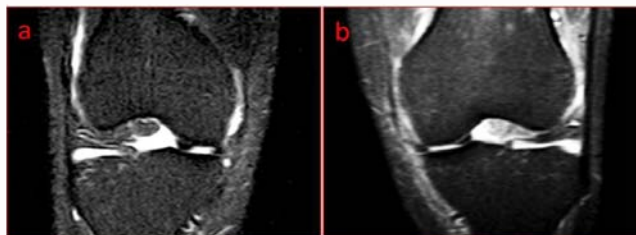


Figure 1: (a) Preoperative MRI frontal scan of the right knee showing a bucket handle tear of the medial meniscus; (b) Preoperative MRI frontal scan of the left knee showing a bucket handle tear of the medial meniscus.

Case 2

In August 2016, a 28-year-old man was admitted to our institution complaining of acute pain on his right knee following a sprain with the knee in full extension (occurring the day before in a non-traumatic setting). The patient referred to impossibility, to regain full knee extension and an episode of giving away with a sudden fall. Physical examination revealed a minimal varus alignment with moderate joint effusion. There was a loss of extension of more than 20°, a slight reduction of knee flexion and a positive Rising Moon sign. Ligaments, patellar facets and the lateral compartment were negative. MRI on the same day showed a displaced bucket-handle of the medial meniscus (Figure 2). Knee arthroscopy was performed the day after confirming the displaced bucket-handle of the medial meniscus. There was no evidence of medial meniscus abnormalities in terms of size and anatomy nor other structures involvement. A Partial medial meniscectomy (meniscal suture was not proposed) was performed. Standard rehabilitation protocol was observed with complete functional recovery. The patient was readmitted in June 2017 for a gradual onset of medial pain to his left knee lasting for two months. No clear trauma was referred. Physical examination on his left knee revealed a minimal varus alignment with slight joint effusion. No signs of ligament laxity were observed. Knee flexion and extension were normal. The rising Moon sign was positive. Both patellar facets were not painful. MRI assessment revealed a medial bucket handled of the medial meniscus as the sole anatomic lesion.

Knee arthroscopy revealed a broken bucket handle of the medial meniscus with a minor flap at the level of the middle third of the meniscus and a major flap dislocated in the notch of the posterior horn. No other intra-articular lesions were observed. A medial meniscectomy, with the removal of both flaps was then performed.

At the latest available examination (August 2020), the patient showed completed pain relief and full ROM and functional recovery.

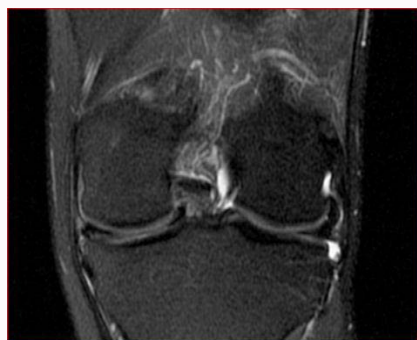

Figure 2: Preoperative MRI frontal scan of the right knee showing a bucket handle tear of the medial meniscus.

Discussion

Bucket handle tears represent 10% to 26% of all meniscus tears and most of them occur non-simultaneously [11,12].

To the best of our knowledge, only 5 cases of bilateral tears have been reported to date [1,4,7,12-15], with 3 of them having a non-simultaneous presentation [4,7,12]. Two distinctive characteristics of the present cases are worth addressing. First, there is a lack of possible factors that can pose a risk for bilateral bucket-handle tears. It has been previously described that complex knee traumas with concomitant ligamentous injuries may increase the risk of a bucket-handle tear, even with a simultaneous bicompartamental presentation [9]. Furthermore, as for non-traumatic bucket-handle tears, there is evidence that a close relationship with meniscal tissue abnormalities exists [2]. Notably, exceptional cases of bilateral Wrisberg discoid menisci misdiagnosed as bucket-handle tears have been also reported [11]. As a further possible risk factor in the development of bilateral bucket-handle tears, Elliot and Rossiter [6] described a unique case of tears of the lateral menisci occurring in a patient suffering from bilateral developmental dysplasia of the hip treated in a Pavlik harness: Authors argued that such treatment should have caused the knee injuries. Differently from what has been reported above, the patients of the current case experienced minor or no traumas, and arthroscopic evaluation of both knees did not reveal meniscal abnormalities nor associated ligamentous injuries concomitant to the meniscal tears.

As a second issue, one of the bucket-handle meniscal tears was located in the red-white zone, thus allowing the surgeon to propose a meniscal suture. To the best of our knowledge, the sole report by Walker and Limbert [15] described a case of bilateral bucket-handle tears of the medial menisci that were both located in the red-white zone. The actual location of the tear is essential when considering the possible outcomes of arthroscopic repair of bucket-handle tears.

In conclusion, the reported clinical cases, together with the lack of known predisposing factors, and the absence of clear traumatic onset lead to the hypothesis of the presence of individual risk factors that are still unknown.

References

- Abbott J, Lam KS, Srivastava VM, Moulton A. Sand pits and bucket handles: A case of bilateral traumatic bucket-handle tears of the medial menisci. *Arthroscopy*. 2000;16:12.
- Akgun I, Heybeli N, Bagatur E, Karadeniz N. Bilateral discoid medial menisci: An adult patient with symmetrical radial tears in both knees. *Arthroscopy*. 1998;14:512-7.
- Cerciello S, Morris BJ, Panni AS, Corona K. The rising moon sign is specific and sensitive in the diagnosis of bucket handle tears of the medial meniscus. *Knee Surg Sports Traumatol Arthrosc*. 2020.
- Day B, Mackenzie WG, Shim SS, Leung G. The vascular and nerve supply of the human meniscus. *Arthroscopy*. 1985;1:58-62.
- Dfouni N, Kindynis PH, Garcia J, Bosson D. [Magnetic resonance imaging in meniscal bucket-handle tears]. *J Radiol*. 1997;78:443-8.
- Elliot RR. Bilateral bucket handle tears of the lateral menisci: A complication of treatment with Pavlik Harness? *Injury*. 2007;38:459-60.
- Greis PE, Lahav A. Bilateral displaced "bucket handle" tears of the medial meniscus in a 16-year-old girl. *J Knee Surg*. 2006;19:41-4.
- Lim WY, Mahmud NA, Peh WC. Clinics in diagnostic imaging (139). Displaced medial meniscus bucket-handle tear. *Singapore Med J*.

- 2012;53:283-7.
9. Lykissas MG, Mataliotakis GI, Paschos N, Panovrakos C, Beris AE, Papageorgiou CD. Simultaneous bicompartamental bucket-handle meniscal tears with intact anterior cruciate ligament: A case report. *J Med Case Rep.* 2010;4:34.
 10. Outerbridge RE. The etiology of chondromalacia patellae. *J Bone Joint Surg Br.* 1961;43-b:752-7.
 11. Sebaaly A, Boueri W, Nabhane L. Bilateral Wrisberg discoid menisci mimicking bucket handle tears associated with osteochondritis dissecans: Case report. *J Pediatr Orthop B.* 2015;24:75-8.
 12. Sezer HB, Arıkan Y, Armagan R, Eren OT. Bilateral bucket handle medial meniscal tears of the knee: A case report. *Int J Surg Case Rep.* 2013;4:926-8.
 13. Shakespeare DT, Rigby HS. The bucket-handle tears of the meniscus. A clinical and arthrographic study. *J Bone Joint Surg Br.* 1983;65:383-7.
 14. Starke C, Kopf S, Petersen W, Becker R. Meniscal repair. *Arthroscopy.* 2009;25:1033-44.
 15. Walker B, Limbert A. Bilateral, simultaneous medial meniscus bucket handle tears in a 23-year-old female. *Case Rep Orthop.* 2014;2014:689130.