



## Atypical Shard “Bullet” Penetrating the Chest

Guiducci GM<sup>1\*</sup>, Kawamukai K<sup>1</sup>, Salomone Di Saverio<sup>2</sup>, Anna M. Parisi<sup>1</sup>, Leuzzi G<sup>3</sup>, Sergio N. Forti Parri<sup>1</sup> and Tugnoli G<sup>2</sup>

<sup>1</sup>Thoracic Surgery Unit, Maggiore and Bellaria Hospitals, Italy

<sup>2</sup>Emergency Surgery and Trauma Surgery Unit, Trauma Center, Maggiore Hospital, Italy

<sup>3</sup>Department of Surgical Oncology, Thoracic Surgery Unit, Regina Elena National Cancer Institute, Italy

### Abstract

A case of a 47-year-old male with a chest wall wound is reported. An accurate understanding of the events was unobtainable from the patient because he was born deaf-mute. The initial suspect of a limited superficial injury, suggested by the absence of major clinical consequences, was contradicted by a subsequent CT scan that revealed a retained metallic foreign body within the chest. The right lung was deeply injured but fortunately without major hemorrhage, although the shard was very close to the superior vena cava. Right thoracotomy was performed and the atypical “bullet” was removed without complications.

**Keywords:** Trauma; Trauma penetrating; Hemothorax; Pleural space

### Case Presentation

A 47 years old Caucasian male was referred to Emergency Department (ED) after being accidentally injured in the right hemi-thorax while handling an angle grinder. Since the patient was born deaf and dumb, it was not possible to completely understand the exact mechanism of trauma.

At the time of ED acceptance, the patient was clinically and hemodynamically stable (blood pressure 130/70, heart rate 105 bpm, and respiratory rate 20 per minute). Physical chest examination showed a 4 cm non-linear laceration of the right anterior chest at para-sternal level, but no retained objects were visible from the injured skin.

For these reasons the presence of a retained metal fragment was not initially suspected by the ED physicians and the patient underwent further standard imaging. Chest X-Ray (Figure 1) and subsequent CT scan (Figure 2, 3a and b) documented a metallic blade-shaped object deeply penetrating pulmonary parenchyma, whose inner end was very close to the superior vena cava. A moderate hemopneumothorax was also evident.

The patient was promptly taken to Operatory Room (OR) and underwent double-lumen intubation and right postero-lateral thoracotomy. The metallic shard was removed without major consequences (Figure 4a and b) and the upper pulmonary lobe was primarily sutured. Antibiotic therapy was early administered and post operative course was substantially uneventful.

### OPEN ACCESS

#### \*Correspondence:

Gian Marco Guiducci, Thoracic Surgery Unit, Maggiore and Bellaria Hospitals, Ospedale Maggiore, Largo Nigrisoli 2, Bologna, Italy, Tel: +39 0516478849; +39 3284288457; E-mail: g.m.guiducci@gmail.com

Received Date: 01 Jul 2016

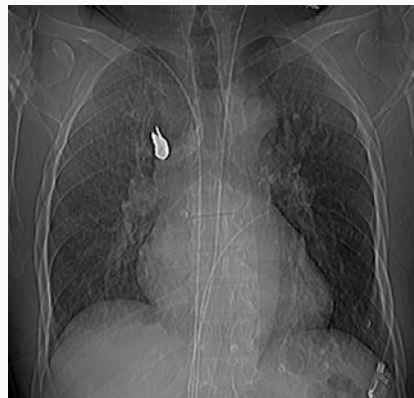Accepted Date: 07 Sep 2016

Published Date: 21 Sep 2016

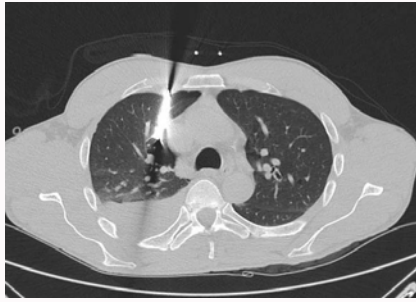#### Citation:

Guiducci GM, Kawamukai K, Di Saverio S, Parisi AM, Leuzzi G, Sergio N. Atypical Shard “Bullet” Penetrating the Chest. *Clin Surg*. 2016; 1: 1134.

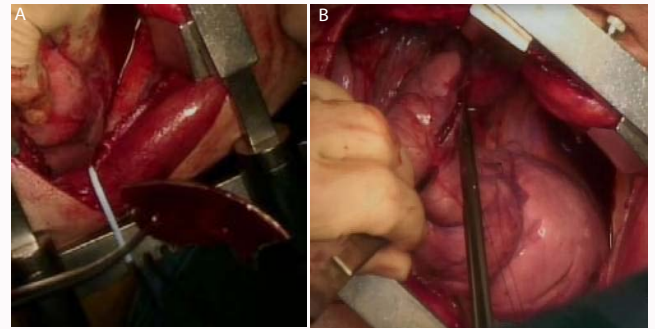
**Copyright** © 2016 Guiducci GM. This is an open access article distributed under the Creative Commons Attribution License, which permits unrestricted use, distribution, and reproduction in any medium, provided the original work is properly cited.



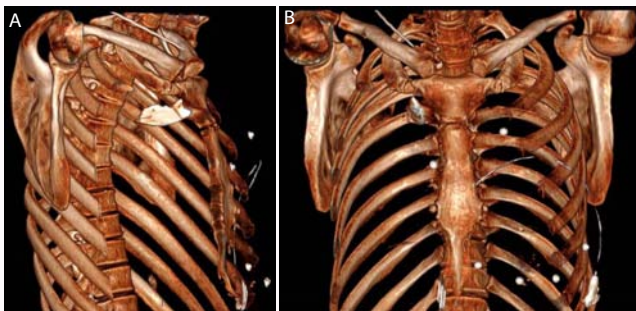
**Figure 1:** Standard Chest X-ray showing metal foreign object in the upper right hemithorax.



**Figure 2:** Chest CT showing the metal shard penetrating the superior lobe of right lung and resting in close proximity of the superior vena cava.



**Figure 4a and 4b:** Surgical field view of the extraction of the metal shard and of the lung laceration suture.



**Figure 3a and 3b:** CT based 3D reconstruction of the rib cage and the location and penetration site of the metal shard right to the sternal manubrium.

## Discussion

Clinical history and physical examination play a cornerstone role in early work-up planning of traumatic injuries. They are essential steps to figure out the correct mechanism of trauma and to guide further diagnostic and treatment steps [1,2].

In this case all vitals were normal and no major symptoms, besides a moderate chest pain, were reported by the patient. Moreover, it was basically impossible to collect an accurate clinical history, since the patient was deaf-mute and no relatives were present at the time of ED admission. All these circumstances prevented immediate and thorough understanding of the cause of trauma. A penetrating metallic fragment was discovered only when the patient underwent imaging.

In a non-military urban scenery, the most likely cause of penetrating chest trauma is knife stabbing [1]. The early diagnostic suspect of ED physicians was oriented towards a superficial chest wall injury since the wound was compatible with a knife stabbing without a retained blade. Surprisingly, CT scan showed a retained metallic foreign body not otherwise clinically detectable.

The absence of haemodynamically symptomatic bleeding allowed the operators to surgically manage the patient with a semi-elective procedure: after obtaining pulmonary exclusion, a standard posterolateral thoracotomy was performed, the metallic shard was removed without any major vascular damage and the superior upper lobe of the right lung was subsequently sutured, as it was the only injury.

In other cases, described in the literature, the retention of knives or other penetrating foreign bodies can provide a momentarily deceptive haemostasis with a tamponade of the great vessel lacerations. Inaccurate or unintentional removal of the knife can lead to a catastrophic hemorrhage [3].

Several Authors advocate Video Assisted Thoracoscopy (VATS) as the approach of choice for thoracic trauma when haemodynamics is permissive [4-6]. We were tempted for a mini-invasive approach, but the potential for major bleeding during extraction led us to prefer an open standard procedure.

Further late complications can be the consequences of concealed foreign bodies migration, contamination and consequent infection of the pleural cavity [7].

When managing penetrating wounds, ED physicians should always consider the possibility of retained foreign bodies despite clinical history and physical examination may apparently exclude such occurrence. Prompt imaging [2] is mandatory in order to avoid early and late complications.

## References

1. Bège T, Berdah SV, Brunet C. Stab wounds in emergency department. *Presse Med.* 2013; 42: 1572-1578.
2. Kavanagh PV, Mason AC, Müller NL. Thoracic foreign bodies in adults. *Clin Radiol.* 1999; 54: 353-360.
3. Sobnach S, Nicol A, Nathire H, Kahn D, Navsaria P. Management of the retained knife blade. *World J Surg.* 2010; 34: 1648-1652.
4. Ben-Nun A, Michael Orlovsky M, Anson Best L. Video-Assisted Thoracoscopic Surgery in the Treatment of Chest Trauma: Long-Term Benefit. *Ann Thorac Surg.* 2007; 83: 383-387.
5. Ahmeda N, Jones D. Video-assisted thoracic surgery: state of the art in trauma care. *Injury.* 2004; 35: 479-489.
6. Williams CG, Haut ER, Ouyang H, Riall TS, Makary M, Efron DT, et al. Video-assisted thoracic surgery removal of foreign bodies after penetrating chest trauma. *J Am Coll Surg.* 2006; 202: 848-852.
7. Petersen K, Waterman P. Prophylaxis and treatment of infections associated with penetrating traumatic injury. *Expert Rev Anti Infect Ther.* 2011; 9: 81-96.