



# <sup>18</sup>F-FDG-PET-CT with Little Value in Different Diagnosis between Pulmonary Malignancy and Amyloidosis

Minghui Liu, Zuoqing Song, Jinghao Liu, Renwang Liu, Hongyu Liu and Jun Chen\*

Department of Lung Cancer Surgery, Tianjin Medical University General Hospital, China

## Abstract

Pulmonary amyloidosis is rare and is often misdiagnosed due a lack of general awareness of the condition. The role of PET-CT in the differential diagnosis between pulmonary amyloidosis and lung malignant tumors is still unclear. Herein, we describe a 61-year-old Chinese woman who presented with a right lower lobe pulmonary nodule, and right hilar and mediastinal lymph nodes shadows. On PET-CT examination, the patient was found to have right lower lung malignant lesions with multiple right hilar and mediastinal lymph node metastases. She was diagnosed with nephrotic syndrome with a history of pathologic type of amyloidosis over the previous two months. After performing right thoracotomy, a histopathologic diagnosis of pulmonary amyloidosis was made. The patient has done well postoperatively, showing no local recurrence in the lung or deterioration of her condition in an over 3-year follow-up period. The pathology of nephrotic syndrome in patients with amyloidosis led to the diagnosis of systemic amyloidosis being made in this patient. From this case, combined with the domestic and international literature, we conclude that PET-CT is of little value for the different diagnosis between pulmonary amyloidosis and lung malignant tumors.

**Keywords:** Amyloidosis; Pulmonary nodule; PET-CT

## Introduction

Amyloidosis is an uncommon disease in which insoluble proteinaceous amyloid fibrils are deposited in body tissues. Pulmonary amyloidosis is rare and is often misdiagnosed due a lack of general awareness of the condition. The role of PET-CT (Positron Emission Tomography-Computed Tomography) in the differential diagnosis between pulmonary amyloidosis and lung malignant tumors is still not clear. We report here a 61-year old female with a right lower lobe pulmonary nodule and right hilar and mediastinal lymph nodes shadows on PET-CT examination that were suspicious of lung carcinoma. Ultimately, the presentation of a systemic amyloidosis with pulmonary amyloidosis was confirmed following the implementation of right thoracotomy plus lung lymph nodes and mediastinal lymph nodes dissection.

## Clinical Data

A 61-year-old female patient was admitted to the hospital with a history of cough, sputum, and bloody sputum for more than one month. These symptoms developed without apparent cause and in the absence of other symptoms such as chest pain/distress, breathlessness, fever, nausea, or vomiting. Unenhanced CT scan of the chest showed a right hilar shadow with an irregular shape in the right lower lobe of lung, and the enlargement of mediastinal lymph nodes (data not shown). The whole body PET-CT (Using <sup>18</sup>F-FDG) examination revealed soft tissue density nodules, about the size of 1.8 cm × 1.1 cm × 1.0 cm, in the right lower hilar area with abnormal tracer concentration of SUV<sub>max</sub> of 3.6, and an abnormal tracer concentration of SUV<sub>max</sub> of 4.9 for subcarinal lymph nodes (Figure 1). The remaining body parts were free of tracer uptake, without signs of malignancy. Hence, the diagnosis was considered to be that of right lower lung malignant lesions with multiple right hilar and mediastinal lymph node metastases.

Two months before the admission, the patient was diagnosed with a nephrotic syndrome with the pathologic type of amyloidosis (Figure 2). The patient had a 13-year history of hypothyroidism, but otherwise denied any history of other conditions. Admission examination found no abnormal signs, and laboratory tests, including tumor markers and tuberculosis PPD test, showed no abnormalities. Since lung cancer could not be excluded, we performed right thoracotomy, and found that the right hilar nodules were actually the enlargements of lymph nodes among lobes. Hence, lung and mediastinal lymph nodes dissection surgery was performed under general anesthesia. As shown

## OPEN ACCESS

### \*Correspondence:

Obi-Njoku Jun Chen, Department of Lung Cancer Surgery, Tianjin Lung Cancer Institute; Tianjin Medical University General Hospital, Heping, Tianjin 300052, China;

E-mail: huntercj2004@yahoo.com

Received Date: 06 Oct 2017

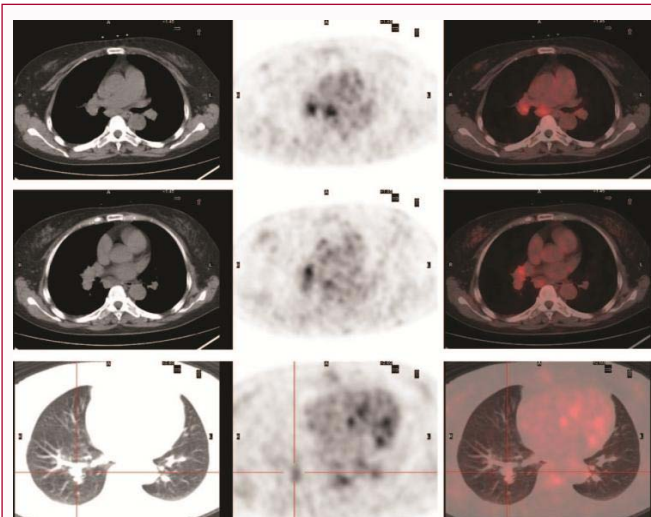
Accepted Date: 22 Nov 2017

Published Date: 01 Dec 2017

### Citation:

Liu M, Song Z, Liu J, Liu R, Liu H, Chen J. <sup>18</sup>F-FDG-PET-CT with Little Value in Different Diagnosis between Pulmonary Malignancy and Amyloidosis. *Clin Surg*. 2017; 2: 1799.

**Copyright** © 2017 Jun Chen. This is an open access article distributed under the Creative Commons Attribution License, which permits unrestricted use, distribution, and reproduction in any medium, provided the original work is properly cited.



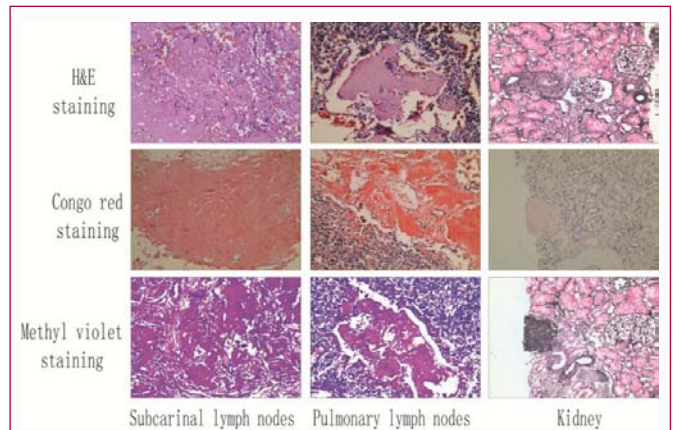
**Figure 1:** Chest PET-CT scans. A: A tumor-like mass with burr contour and an irregular margin was demonstrated in the right lower lung with an abnormal elevated concentration of  $SUV_{max}$  of 3.6; B and C: The enlarged mediastinal lymph nodes have an elevated  $SUV_{max}$  of 4.9.

in Figure 2, subsequent histopathologic examination showed that fat and fibrous tissues and lymph nodes were seen in homogeneous red dye substances in mediastinal and multiple pulmonary lymph nodes, surrounded with a few plasma cells and large amounts of lymphocytes; and a diagnosis of amyloid was confirmed, supported by Congo red- and methyl violet-positive staining. The patient's postoperative course was uneventful. She was discharged seven days after surgery and attended the internal physicians for further treatment of amyloidosis. There was no local recurrence in the lung or deterioration of the patient's condition in an over 3-years follow-up period.

## Discussion

Amyloidosis, first described in 1854 by Virchow, is a group of different clinical manifestations of a syndrome, which have in common the abnormal deposition of the substance amyloid in diseased tissue [1]. According to whether lesions involve single or multiple sites, the disease is divided into localized and systemic amyloidosis. The most common sites in which amyloidosis are involved are: kidneys, cardiovascular system, gastrointestinal tract and liver. Respiratory system involvement is relatively rare; only in about 20% of patients with systemic amyloidosis is the respiratory system involved. This case is one of systemic amyloidosis with respiratory system involvement, since the amyloidosis was confirmed by pathology examination of kidneys and of lymph nodes from lung and mediastinum. Systemic amyloidosis, also known as immunoglobulin light chain-related amyloidosis, is the most commonly-occurring type of amyloidosis and is the most rapidly progressive [2].

In patients with systemic amyloidosis, with the accumulation of lesions in different regions, the clinical manifestations vary in severity from light symptoms and occasional findings on physical examination, to death [3]. The average survival time of systemic amyloidosis is 12 to 15 months, and if involving the heart, the average survival time is less than five months [4]. Because of atypical clinical manifestations of the disease, and the lack of specificity of diagnostic imaging, it is very difficult to make the diagnosis and differential diagnosis, especially for lung and mediastinum nodular amyloidosis.



**Figure 2:** Pathological examination ( $\times 100$ ). Upper panel: HE staining showed that mediastinal lymph nodes, pulmonary lymph nodes and kidney were all characterized by amyloidosis; Histochemical staining showed amyloid positive stained with Congo red and Methyl violet. Congo red staining was pink (Middle panel), and Methyl violet staining was purple (Lower panel).

From images, it is very difficult to distinguish among primary lung tumors, lung metastases, other lung inflammatory pseudo tumors, and lung/mediastinum nodular amyloidosis [5]. However, CT-guided percutaneous needle biopsy or endoscopic ultrasound biopsy has the greater value in the diagnosis of these diseases [6,7]. So far, the gold standard for the diagnosis of amyloidosis is the histological examination of biopsy tissues through Congo red (pink or rose red) and methyl violet (red or purple) staining, and polarized light microscopy showing the characteristic yellow-green two-color of double refraction bodies [8]. Gould [9] has reported that PET-CT in lung nodules with a diameter greater than 1 cm is one type of very accurate noninvasive method. In this patient, PET-CT examination showed that the nodules in the right lower lung hilar region had a visible high metabolism of  $SUV_{max}$  of 3.6, and the abnormal tracer concentration of  $SUV_{max}$  of 4.9 for subcarinal lymph nodes, considered as malignant lesions with multiple right hilar and mediastinal lymph node metastasis. However, the pathological diagnosis for the patient is that of amyloidosis. Glaudemans [10] considered PET-CT to be of great value in differentiating systemic and localized amyloidosis. In systemic amyloidosis, PET-CT imaging revealed a negative amyloid deposition area in most cases, while amyloid deposition in localized amyloidosis was positive in most cases. Son et al. [11] reported one case of localized hepatic amyloidosis which was concentrated by  $^{18}F$ -FDG PET/CT detection and Mekinian et al. [12] reported one case of systemic amyloidosis which was almost negative in the whole body, with the exception of joints with high metabolic concentration with PET/CT scan. Costantino et al. [13] reported that two cases of localized amyloidosis in bone and muscle respectively did not appear to have a high metabolic concentration with PET/CT scan and Mainenti et al. [14]. Showed in two cases of localized intestinal amyloidosis that each case had different patterns of clinical and imaging presentation, especially for one case with negative concentration by PET/CT detection. Furthermore, Mekinian et al. [15] presented a study of the PET/CT role in amyloidosis in which 10 cases of amyloidosis patients were collected, including four cases of localized amyloidosis and six cases of systemic amyloidosis. The results showed that three of four cases of localized amyloidosis were positive with PET/CT scan, while four of six cases of systemic amyloidosis were positive with PET/CT scan. In our case, the patient was diagnosed with nephrotic syndrome of amyloidosis before admission and failed to show a positive result

in the kidneys with PET/CT scan. On the other hand, the PET/CT suggested that, in pulmonary nodules and mediastinal lymph nodes, there was a high metabolic concentration with PET/CT scans, leading to a diagnosis of malignant lesions. Overall, although PET/CT cannot observe the anatomical characteristics of lesions, it can nevertheless observe the functional changes of lesions. PET/CT has a very important role in distinguishing among primary lung cancer, lung metastasis and benign lesions in the lung. But it nevertheless has some limitations, such as in distinguishing between malignant lung lesions and pulmonary amyloidosis, and in distinguishing between localized and systemic amyloidosis. The role of PET/CT in the diagnosis and differentiation of amyloidosis may have limitations, and still needs to be further explored.

## Acknowledgement

**Funding:** This research is partially supported by grants from the Science and Technology Support Key Program of Tianjin (12ZCDZSY16100), the Tianjin Natural Science Foundation (12JCZDJC24400), and the project of Ministry of Education for New Century Excellent Talents (NCET-10-0956). Funding sources had no role in study design, data collection, and analysis; in the decision to publish; or in the preparation of the manuscript.

**Authors contributions:** MHL and ZQS collected all data and authored the manuscript. ZQS, JHL, and RWL were responsible for patient care and analysis of follow-up data. HYL analyzed the data and provided histopathologic confirmation. JC performed the surgical procedure, and also contributed to data analysis and shaping of the manuscript. All authors have read and approved the final manuscript.

## References

1. Khan MF, Falk RH. Amyloidosis. *Postgrad Med J*. 2001;77(913):686-93.
2. Cohen AD, Comenzo RL. Systemic light-chain amyloidosis: advances in diagnosis, prognosis, and therapy. *Hematology Am Soc Hematol Educ Program*. 2010;2010:287-94.
3. Comenzo RL. How I treat amyloidosis. *Blood*. 2009;114(15):3147-57.
4. Esplin BL, Gertz MA. Current trends in diagnosis and management of cardiac amyloidosis. *Curr Probl Cardiol*. 2013;38(2):53-96.
5. Liu M, Wei S, Li X, Liu H, Zhou Q, Chen J. Pulmonary nodular amyloidosis in a patient undergoing lobectomy: a case report. *J Med Case Rep*. 2013;7(1):248.
6. BoydKing A, Sharma O, Stevenson K. Localized interstitial pulmonary amyloid: a case report and review of the literature. *Curr Opin Pulm Med*. 2009;15(5):517-20.
7. Fukatsu H, Miyoshi H, Ishiki K. Spontaneous resolution of multiple nodular pulmonary AA amyloidosis. *Intern Med*. 2010;49(21):2303-7.
8. Mollee P, Tate J, Pretorius CJ. Evaluation of the N Latex free light chain assay in the diagnosis and monitoring of AL amyloidosis. *Clin Chem Lab Med*. 2013;51(12):2303-10.
9. Gould MK, Maclean CC, Kuschner WG, Rydzak CE, Owens DK. Accuracy of positron emission tomography for diagnosis of pulmonary nodules and mass lesions: a meta-analysis. *JAMA*. 2001;285(7):914-24.
10. Glaudemans AW, Slart RH, Noordzij W, Dierckx RA, Hazenberg BP. Utility of 18F-FDG PET/(CT) in patients with systemic and localized amyloidosis. *Eur J Nucl Med Mol Imaging*. 2013;40(7):1095-101.
11. Son YM, Choi JY, Bak CH, Cheon M, Kim YE, Lee KH, et al. 18F-FDG PET/CT in primary AL hepatic amyloidosis associated with multiple myeloma. *Korean J Radiol*. 2011;12(5):634-7.
12. Mekinian A, Ghrenassia E, Pop G, Roberts S, Prendki V, Stirnemann J, et al. Visualization of amyloid arthropathy in light-chain systemic amyloidosis on <sup>18</sup>F-FDG PET/CT scan. *Clin Nucl Med*. 2011;36(1):52-3.
13. Costantino F, Loeuille D, Dintinger H, Pere P, Chary-Valckenaere I. Fixed digital contractures revealing light-chain amyloidosis. *Joint Bone Spine*. 2009;76(5):553-5.
14. Mainenti PP, Segreto S, Mancini M, Rispo A, Cozzolino I, Masone S, et al. Intestinal amyloidosis: two cases with different patterns of clinical and imaging presentation. *World J Gastroenterol*. 2010;16(20):2566-70.
15. Mekinian A, Jaccard A, Soussan M, Launay D, Berthier S, Federici L, et al. <sup>18</sup>F-FDG PET/CT in patients with amyloid light-chain amyloidosis: case-series and literature review. *Amyloid*. 2012;19(2):94-8.